

A man with short dark hair, wearing a light-colored button-down shirt with dark sleeves and dark trousers, stands in front of a large, multi-tiered artificial waterfall. The waterfall is constructed from large, stacked, reddish-brown rocks. Water is cascading down the rocks. In the background, there is a building with large windows and some potted plants on the left. The text "P.M Poultry Diseases 4th year series" is overlaid in large, bold, black font across the center of the image.

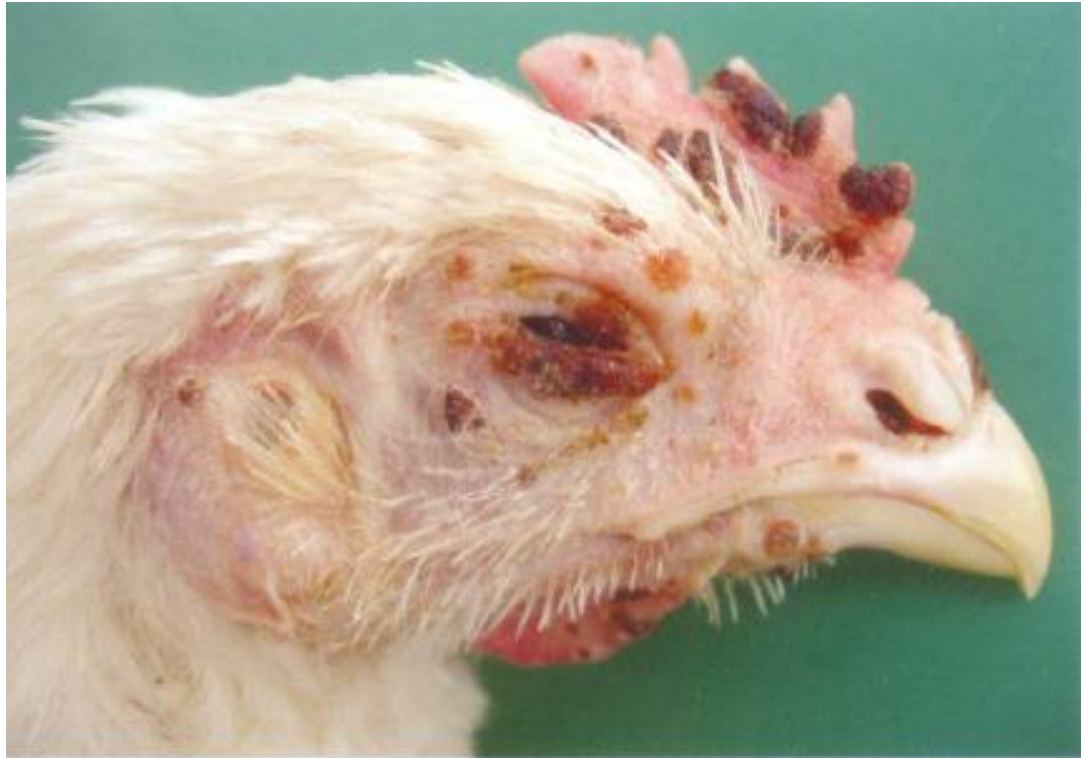P.M Poultry Diseases 4th year series

By Mohamed Mahmoud Salem gab Allah
Assistant lecturer of pathology
Faculty of Veterinary Medicine, Benha
University, Moshtohor,
Tukh; 13736 , Qalyuobia, EGYPT

FOWL POX

265, 266.

Fowl pox (FP) is a viral disease in hens, turkeys and many other birds, characterized by cutaneous lesions on the featherless skin and/or diphtheritic lesions of mucous coats of the upper alimentary and respiratory tract. FP is encountered in either cutaneous or diphtheritic form or in both. In most outbreaks, the cutaneous form is prevailing. The lesions vary according to the stage of development: papules, vesicles, pustules or crusts. The lesions are usually in the region of the head.



FOWL POX

265, 266.

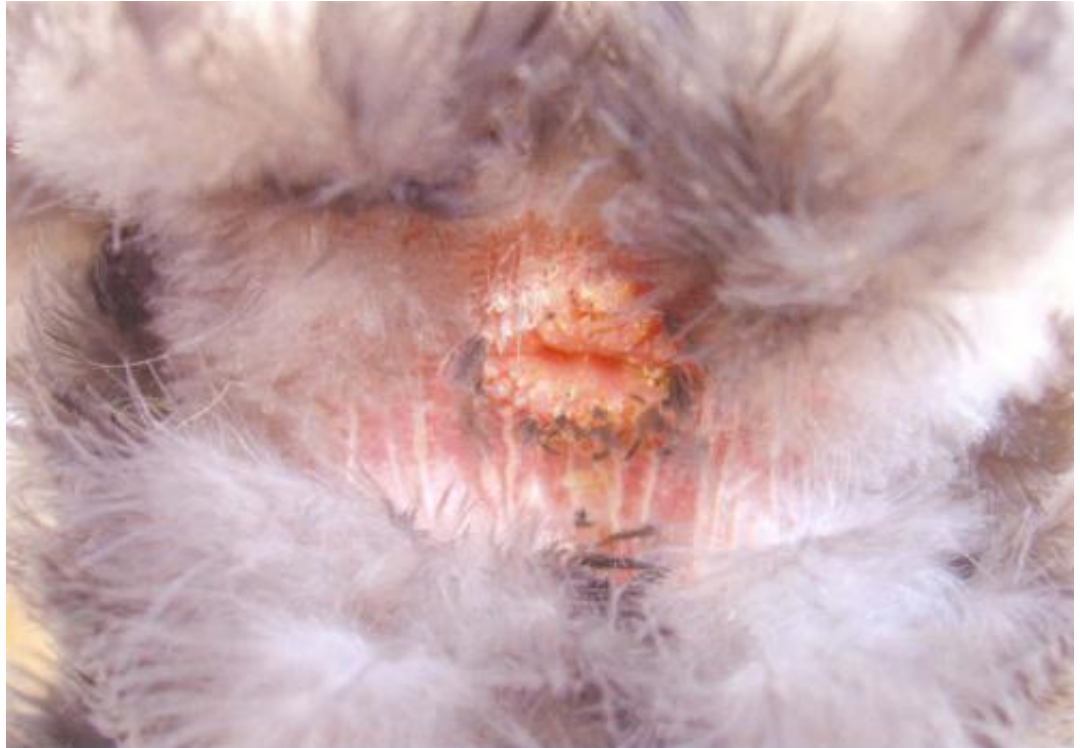Fowl pox (FP) is a viral disease in hens, turkeys and many other birds, characterized by cutaneous lesions on the featherless skin and/or diphtheritic lesions of mucous coats of the upper alimentary and respiratory tract. FP is encountered in either cutaneous or diphtheritic form or in both. In most outbreaks, the cutaneous form is prevailing. The lesions vary according to the stage of development: papules, vesicles, pustules or crusts. The lesions are usually in the region of the head.



FOWL POX

267. FP lesions around the vent in a pigeon.

FP is caused by an epitheliotropic DNA virus from the Avipox genus, the Poxviridae family. Some virus types (strains) exist: fowl pox virus, turkey pox virus, pigeon pox virus, canary pox virus etc., different in pathogenic and immunogenic aspects. The viruses are very resistant to environmental factors and could persist for several months.



FOWL POX

268, 269.

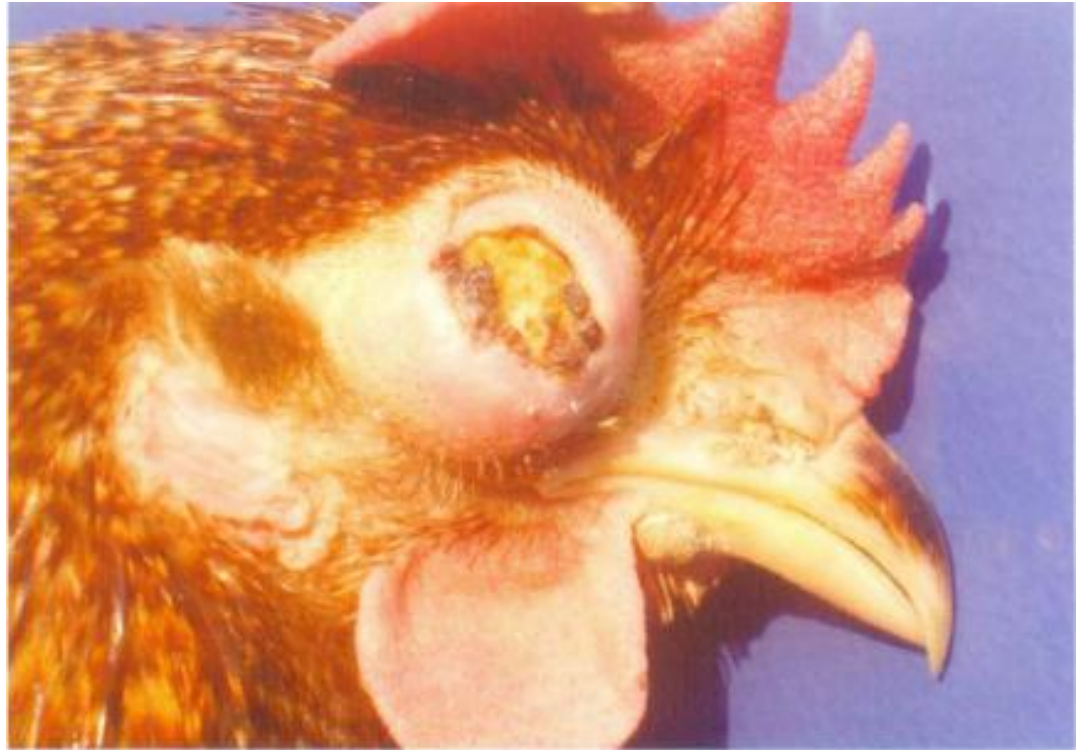Frequently, the conjunctival mucosa, injured by the pox virus, is an entrance door for additional contamination (*E. coli*, *Staphylococcus spp.* etc.) and development of complications. The infection is mechanically spread by dissemination of the virus through desquamation of crusts that contain it. Some mosquitoes and blood suckling arthropods could also distribute the virus. The mosquitoes remain infective for several weeks. The incubation period is from 4 to 10 days. The disease is spread slowly and many weeks could pass between its emergence and severe outbreaks



FOWL POX

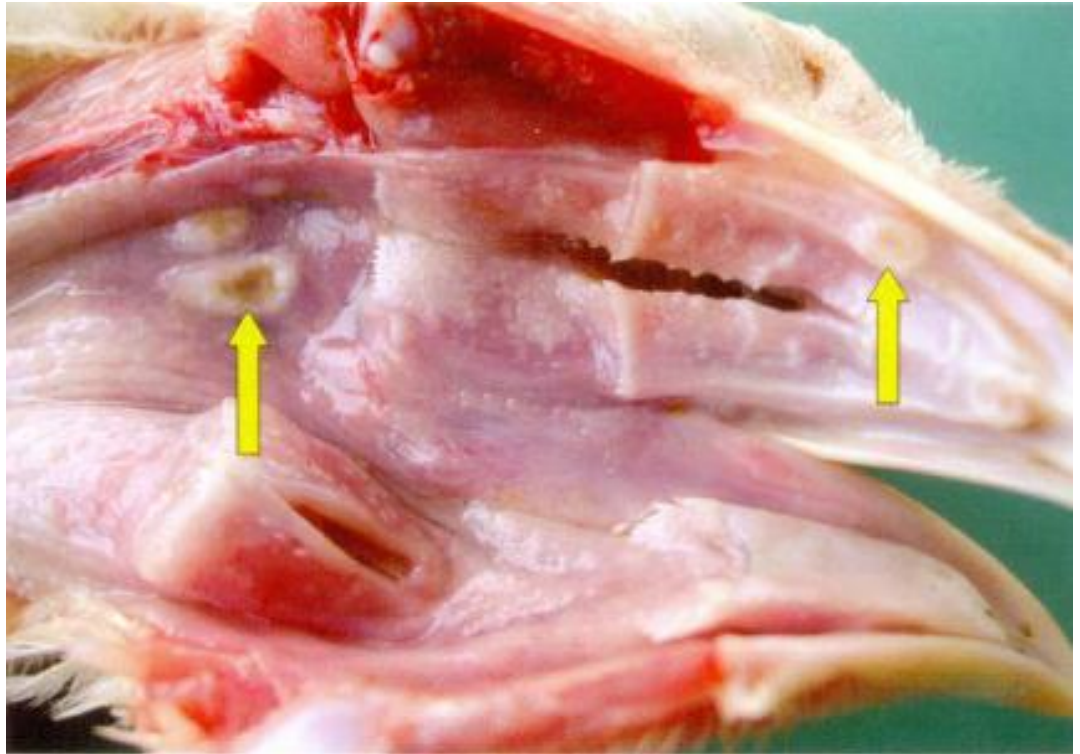
268, 269.

Frequently, the conjunctival mucosa, injured by the pox virus, is an entrance door for additional contamination (*E. coli*, *Staphylococcus spp.* etc.) and development of complications. The infection is mechanically spread by dissemination of the virus through desquamation of crusts that contain it. Some mosquitoes and blood suckling arthropods could also distribute the virus. The mosquitoes remain infective for several weeks. The incubation period is from 4 to 10 days. The disease is spread slowly and many weeks could pass between its emergence and severe outbreaks



FOWL POX

270. Diphtheritic lesions look like whitish or yellowish plaques that are deposited and grown on the mucous coats of the buccal and nasal cavities, the sinuses, the larynx, the pharynx, the trachea or the oesophagus (arrows). The diagnosis is made upon the typical cutaneous and diphtheritic lesions. The prevention is performed by vaccinations that could be made at any age, if necessary.



FOWL POX



Avian pox

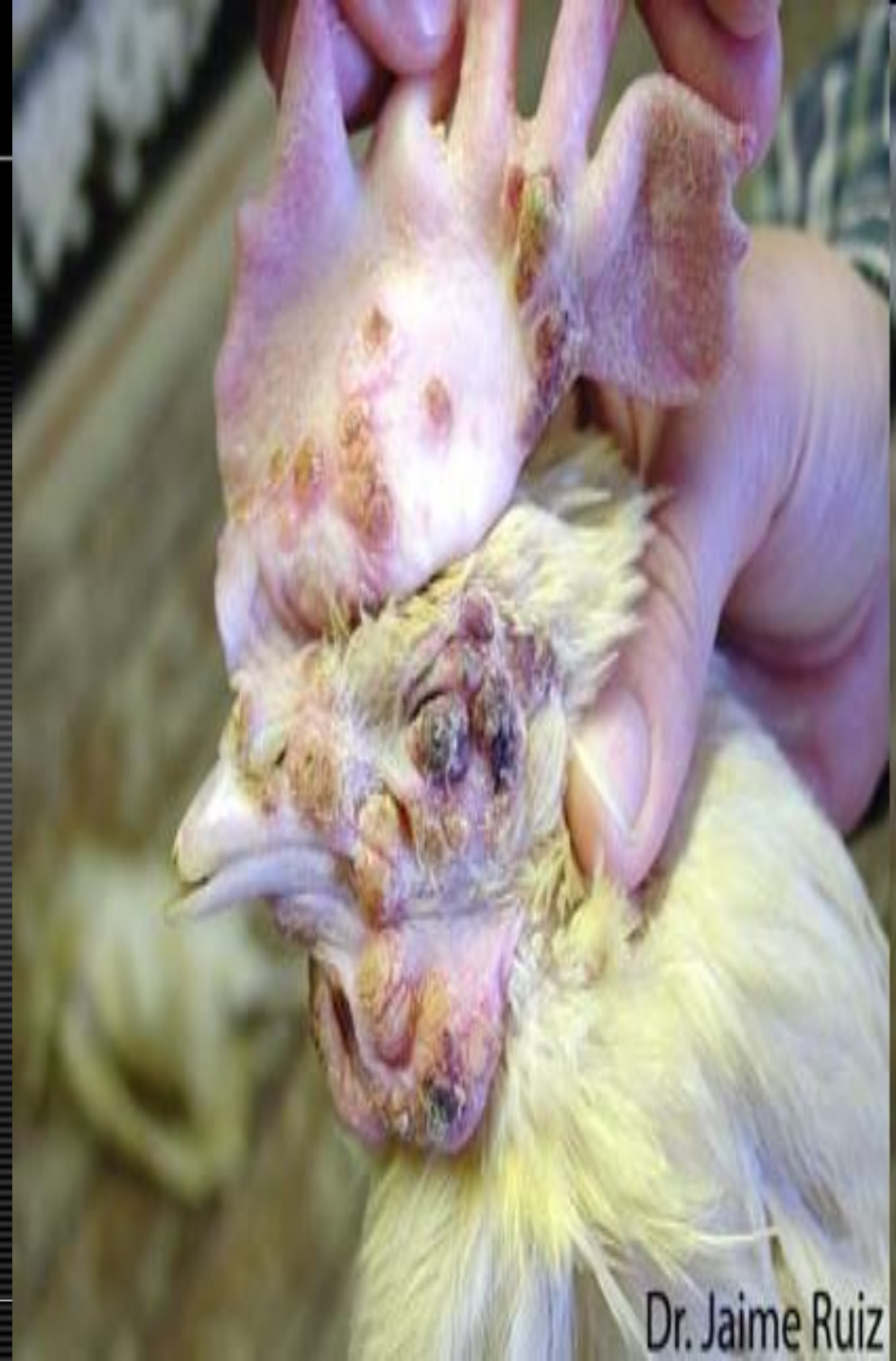Avian pox

- Morphologic Diagnosis
- **Skin, comb: Severe locally epidermal hyperplasia with ulcers**
- Clinical Description
- **There are numerous nodular proliferative scabs on the comb, wattles and eyelids of this bird. These scabs are consistent with the cutaneous, or dry form of avian pox virus. Cutaneous pox primarily affects the non-feathered areas of the body.**
- Pathologic Description
- **A large area of the skin covering the caudal comb is distorted by multiple variably sized and shaped, sometimes coalescing, dry, raised, encrusted areas. The centers of some of these areas are sunken and the surfaces are often ulcerated.**



Avian pox

- Morphologic Diagnosis
- **Skin (unfeathered): Multifocal hyperplastic and ulcerative dermatitis.**
- Clinical Description
- **This image shows the dry form of avian pox with cutaneous hyperplastic lesions of the face, wattles, and comb. The formation of scabs is typical in this form of Avian Pox.**
- Pathologic Description
- **The unfeathered portions of the skin are covered by multiple, well-demarcated, raised, nodular masses. Many of the masses are covered by layers of dry, tan, flaky tissue. Some of the lesions are rimmed by reddened skin and some are covered by red scabs. The masses impinge on the nare, eye, and commissure of the beak.**



Avian pox

- Morphologic Diagnosis
- **Skin (unfeathered): Multifocal hyperplasia with hyperkeratosis.**
- Clinical Description
- **This image shows a mild case of the dry form of avian pox with cutaneous hyperplastic lesions of the face and comb.**
- Pathologic Description
- **The skin on the face and comb is covered by multiple small, well-demarcated, slightly raise, brown, dry plaques. The plaques are roughly circular but have an irregular margin.**



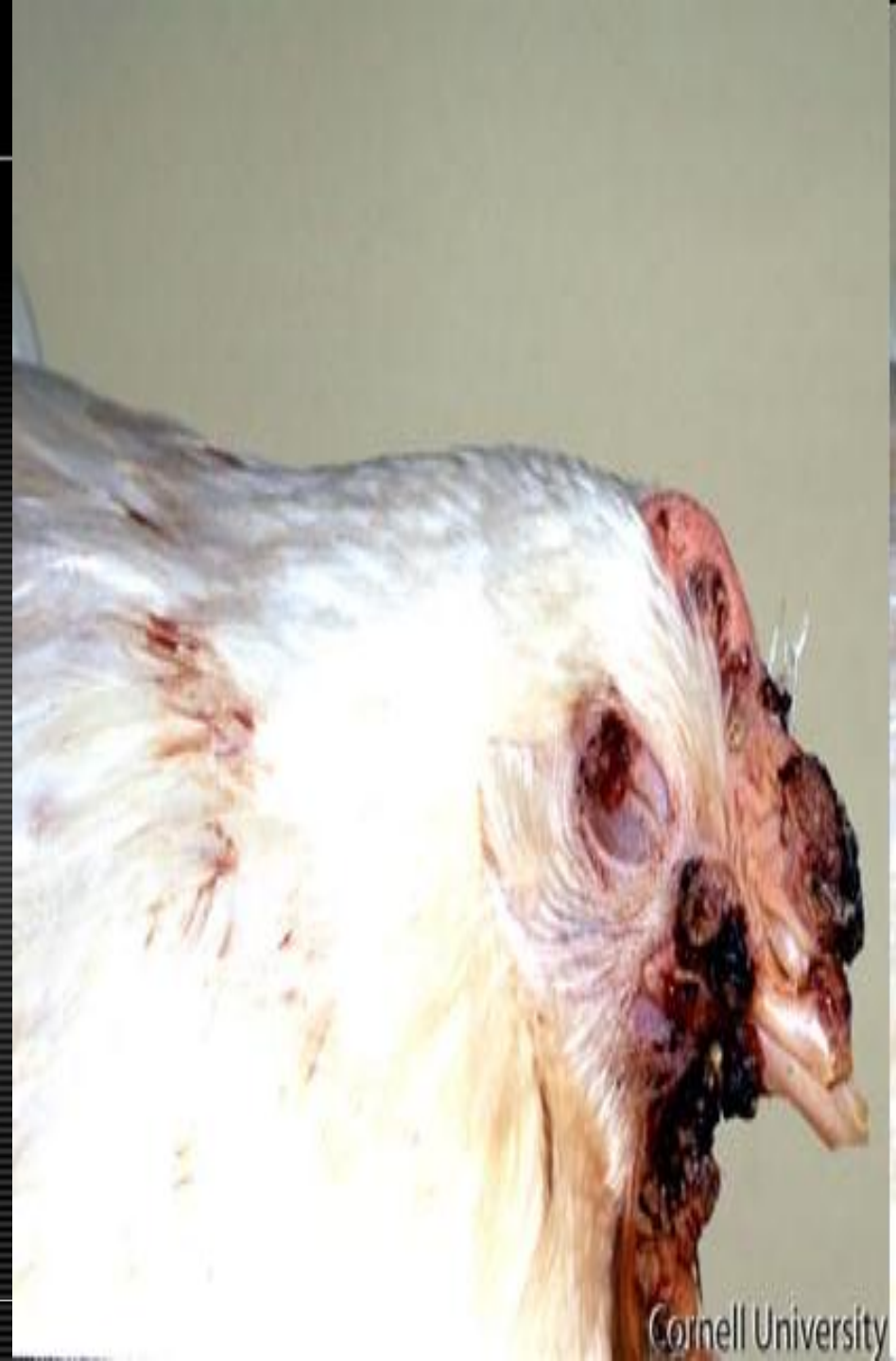Avian pox

- Morphologic Diagnosis
- **Conjunctiva: Mild acute conjunctivitis.**
- Clinical Description
- **In the earlier stages of pox virus, shown here, the eyes and eyelids may become involved. The resulting conjunctivitis is a non-specific finding for pox virus and other diseases that affect the head and upper respiratory tract must be ruled out.**
- Pathologic Description
- **The conjunctiva is swollen, wet and slightly red.**



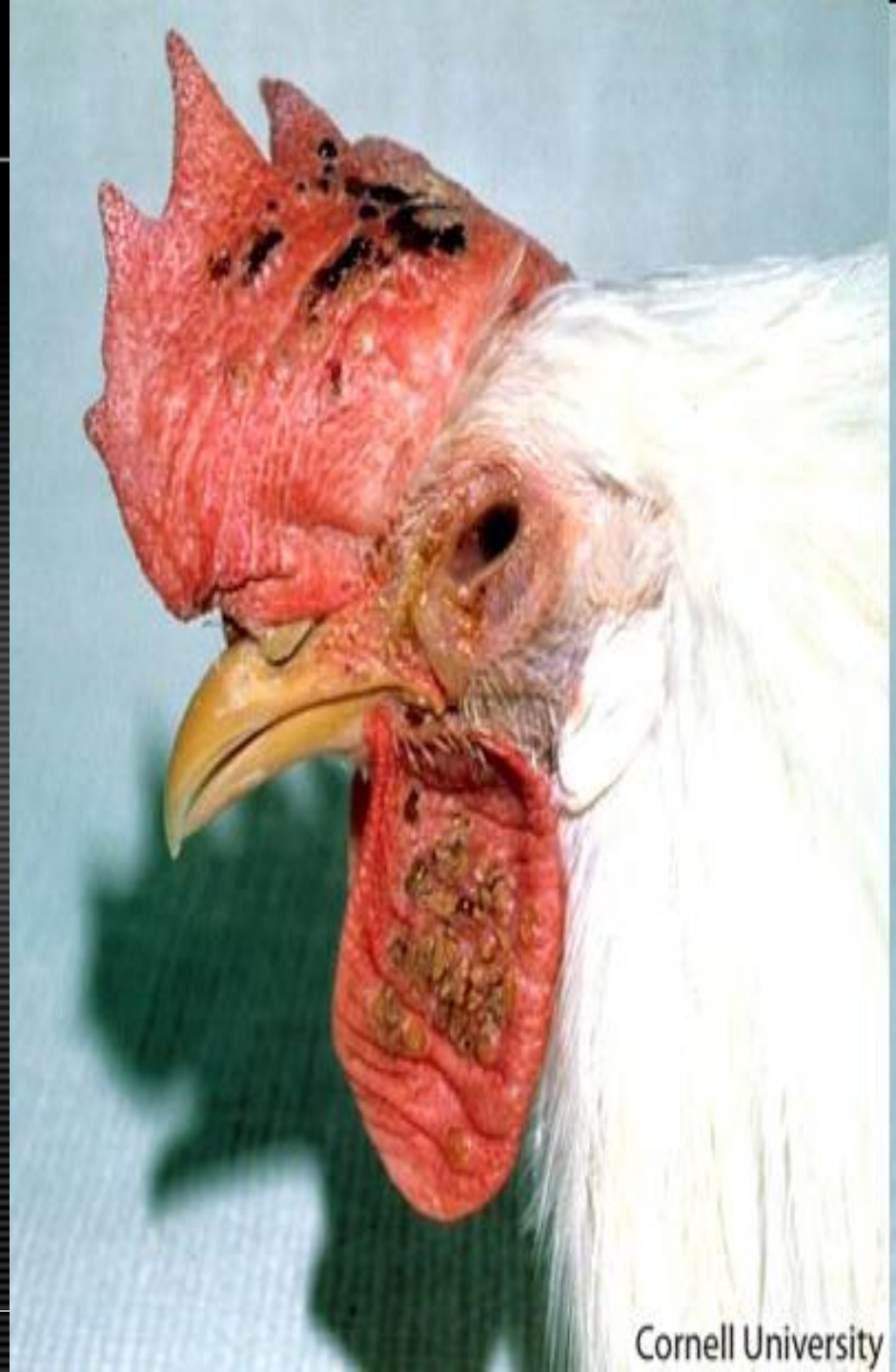Avian pox

- Morphologic Diagnosis
- **Skin (unfeathered): Severe multifocal to coalescing hyperplasia with ulceration.**
- Clinical Description
- **Cutaneous (dry) form of avian pox with proliferative lesions and scab formation on the comb, wattles, and eyelid. In some cases, the eyelids can become so severely affected that vision is obstructed.**
- Pathologic Description
- **The unfeathered skin of the face, comb and wattles is covered by multiple, irregular dry, tan nodules that are often ulcerated and encrusted with dried serum and blood. The nodules vary in size and sometime coalesce. This is particularly evident on the comb and cranial portion of the wattle. The lesion on the eye impinges on the ability of the eye to open.**



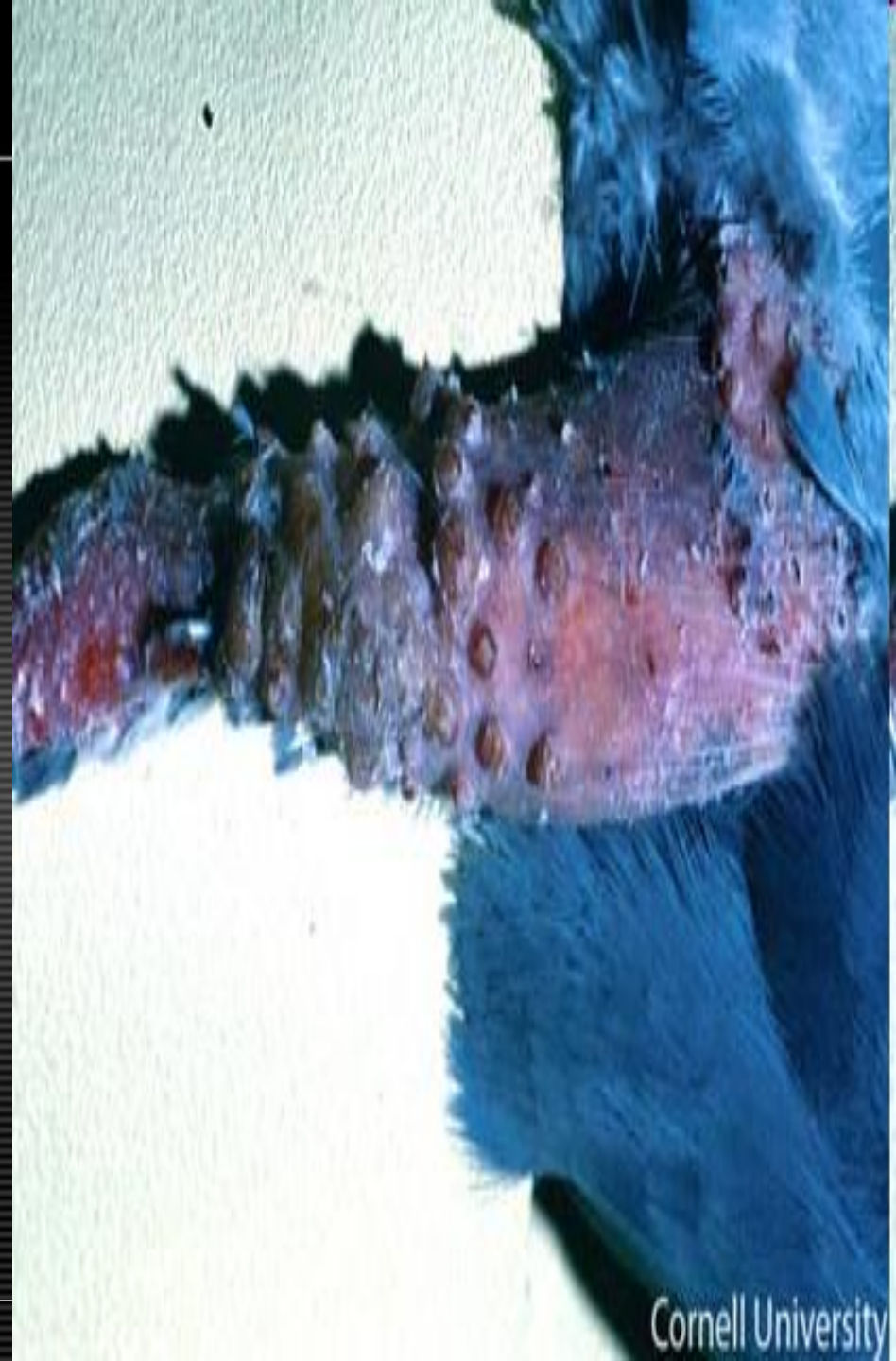Avian pox

- Morphologic Diagnosis
- **Unfeathered skin: Moderate hyperplasia with ulceration. Conjunctiva: Moderate suppurative conjunctivitis.**
- Clinical Description
- **In this photograph, a late stage of the cutaneous (dry) form of avian pox is illustrated in the comb, wattles, and periocular region. Pox virus is slow-spreading and skin lesions change over a period of approximately 2-8 weeks. Lesions progress from nodules, to small white foci, papules, vesicles, scabs (seen here), and eventually scars.**
- Pathologic Description
- **The unfeathered skin on the head is covered by multiple, well-demarcated, irregularly contoured plaques of tan, dry, flaky tissue. The plaques on the comb are often covered by dried blood. Those on the wattle, are coalescing and covered by smaller scabs. The conjunctiva is swollen and pale tan mucoid material oozes from the medial canthus of the eye.**



Avian pox

- Morphologic Diagnosis
- **Skin, leg: Severe multifocal to locally extensive nodular follicular epidermal hyperplasia with dermatitis**
- Clinical Description
- **In this photograph, an advanced stage of the cutaneous (dry) form of avian pox is illustrated. Pox virus is slow-spreading and skin lesions change over a period of several weeks. Lesions progress from nodules, to small white foci, papules, vesicles, scabs, and eventually scars. In this photo, the lesions are beginning to coalesce into rough brown scabs. At this stage, if the scabs are disrupted, as seen on this distal limb, a seropurulent exudate may be observed.**
- Pathologic Description
- **The skin and leg are disrupted by multiple well-demarcated raised round nodules. At the distal aspect of the leg, these nodules coalesce to form a confluent, raised, irregularly-shaped, brown scab. Because the individual lesions are regular in shape, size, and distribution, it is likely that they correspond to a normal anatomic structure. In this case, they correspond to the feather follicles.**



Avian pox

- Morphologic Diagnosis
- **Skin (head): Moderate multifocal to coalescing hyperplasia with hyperkeratosis and ulceration.**
- Clinical Description
- **In the later stages of the dry form of Avian Pox, shown here, the cutaneous lesions on the wattles and comb have progressed into vesicles, exhibiting thick, rough, brown scabs. Some of the lesions have coalesced.**
- Pathologic Description
- **The unfeathered skin of the head is covered by numerous, randomly arranged, well-demarcated, slightly raised plaques of brown, rough tissue. In areas, these plaques coalesce to form large lesions. A few of the plaques are covered by scabs.**



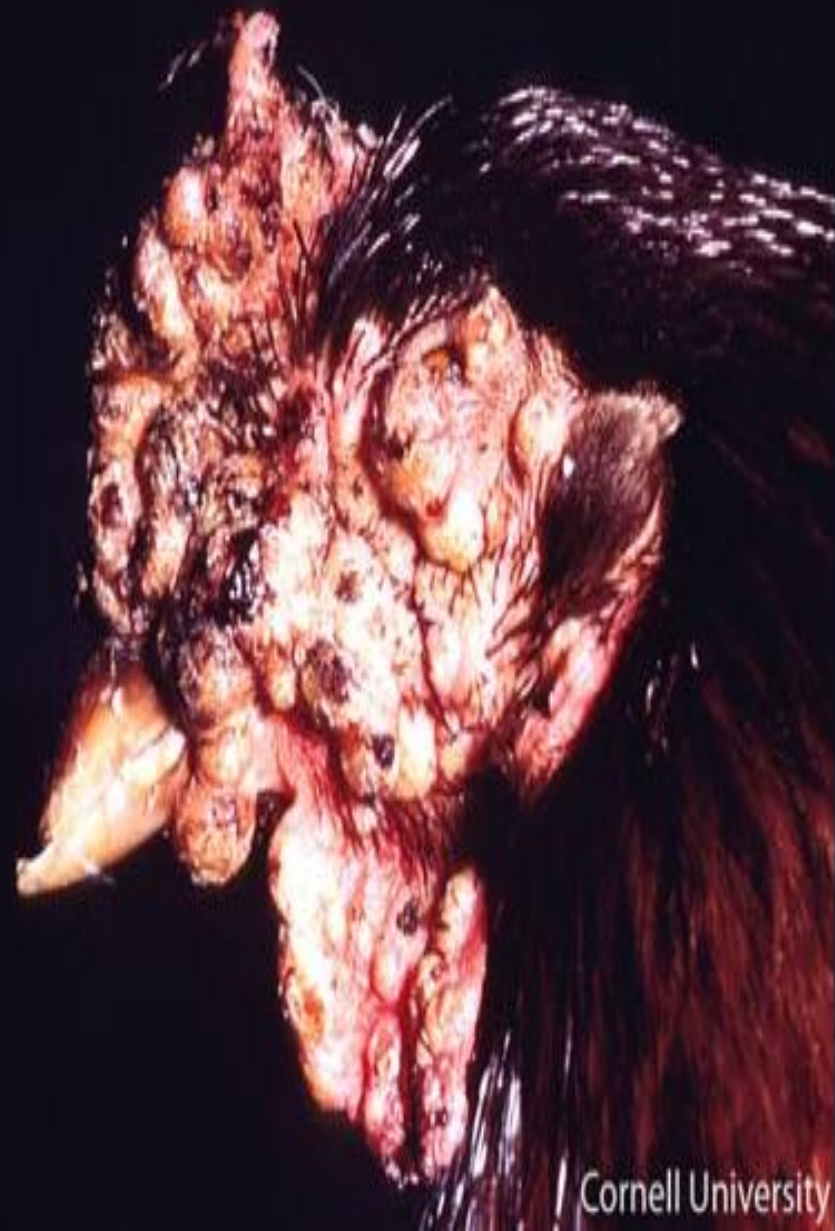Avian pox

- Morphologic Diagnosis
- **Skin, head: Severe locally extensive epidermal hyperplasia with alopecia**
- Clinical Description
- **This image shows numerous raised nodules on the head. In addition to poultry, the pox virus has been reported to infect many species of domestic and wild birds.**
- Pathologic Description
- **Feathers are missing from a large area of this bird's head. The underlying skin is covered by numerous well-demarcated slightly raised nodules.**



Avian pox

- Morphologic Diagnosis
- **Skin (head): Severe multifocal to coalescing nodular hyperplasia with ulceration.**
- Clinical Description
- **This image depicts diffuse large nodular lesions on the entire head area.**
- Pathologic Description
- **The skin of the entire head is covered by multiple, coalescing nodules that impinge on the nares, mouth and eyes. The nodules are pale yellow to tan and many of them are covered by crusts of blood and serum.**

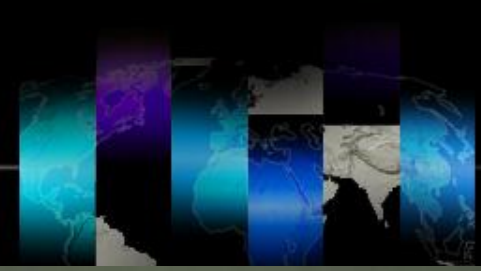

Avian pox

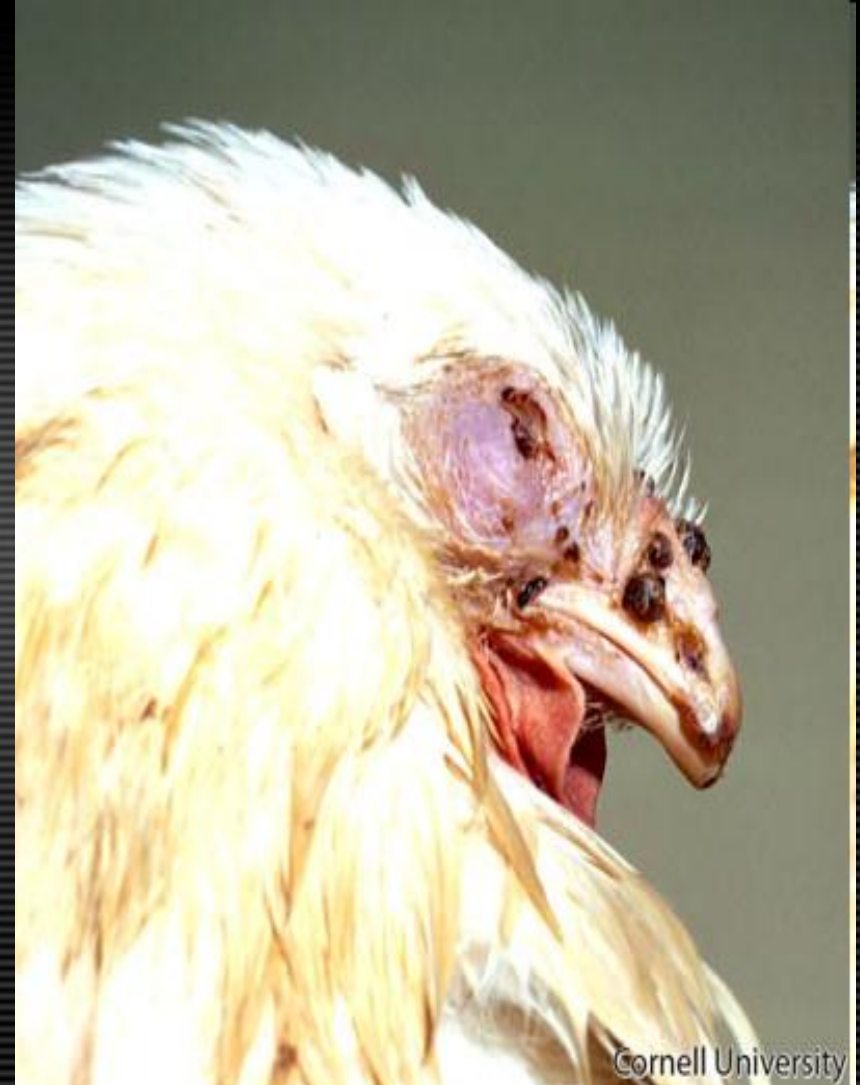- Morphologic Diagnosis
- **Skin (back): Severe hyperplasia with hyperkeratosis.**
- Clinical Description
- **This image shows the dry, or cutaneous, form of avian pox. There are many pox lesions along the dorsum of this table-egg layer. Pox lesions typically develop on the head and legs however, in rare cases, they may extend into other regions of the body. The lesions are cutaneous nodules of epithelial hyperplasia arising from the epidermis and feather follicles.**
- Pathologic Description
- **The skin along the back of this bird is covered by numerous, irregularly-shaped, well-demarcated, sometimes coalescing raised, grey plaques. The surfaces of the lesions are granular, rough and dry.**



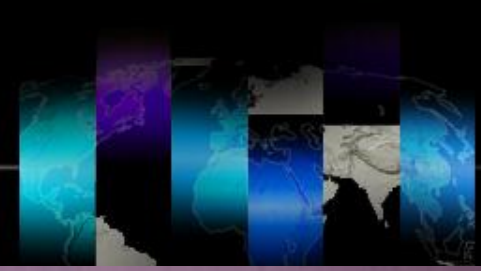Avian pox



- Morphologic Diagnosis
- **Skin: Moderate multifocal proliferative and ulcerative dermatitis.**
- Clinical Description
- **Cutaneous (dry) form of avian pox with proliferative lesions and scab formation on the skin around the nare and eyelid.**
- Pathologic Description
- **The skin of the eyelid, commissure of the beak, cere, and nare is expanded by multiple, well-demarcated nodules covered by scabs of dried brown blood and serum. The masses impinge on the nare and eyelid.**



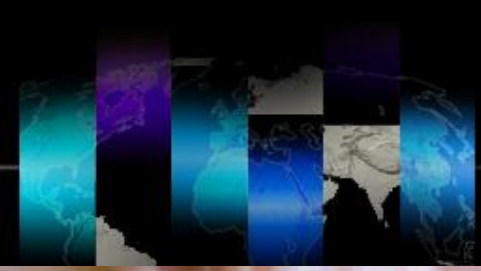Avian pox



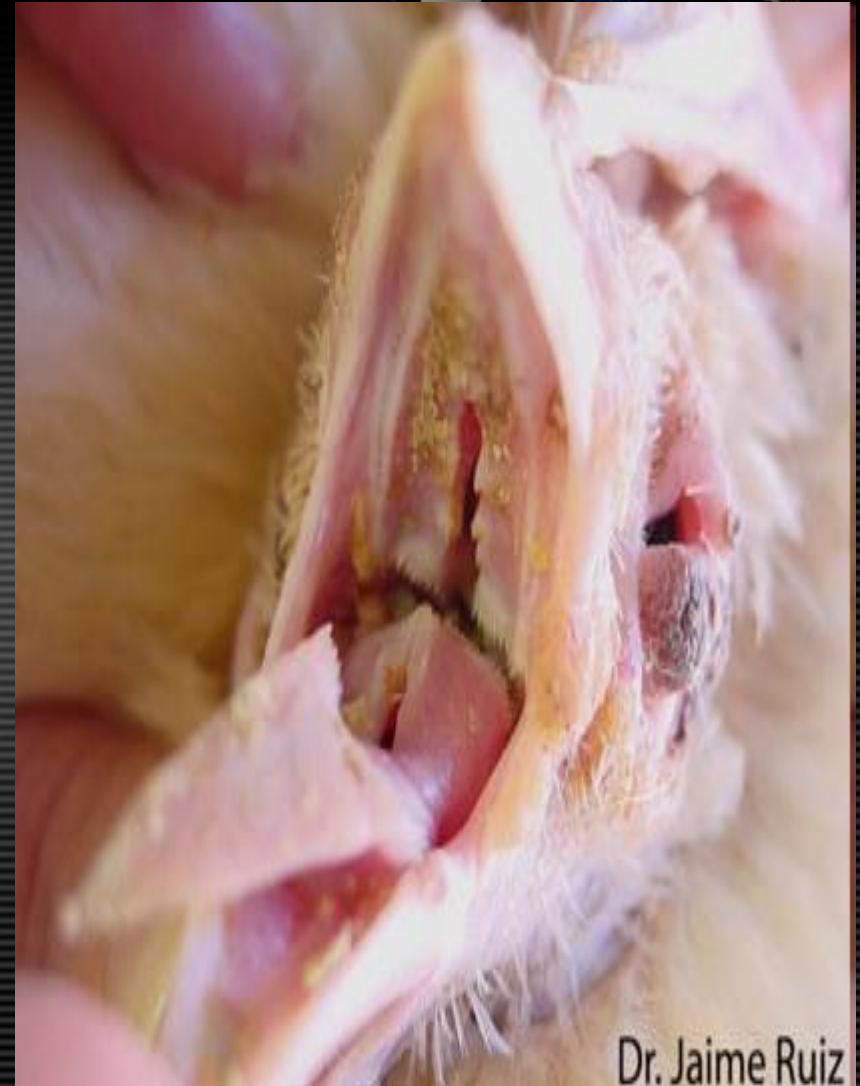- Morphologic Diagnosis
- **Skin (eye and mouth): Mild locally extensive hyperplasia with hyperkeratosis.**
- Clinical Description
- **This bird has cutaneous proliferative lesions around the eyes and mouth. These lesions can persist for about 3-4 weeks or longer and may interfere with normal functions, such as eating. In canaries, pox is associated with systemic infections and high mortality.**
- Pathologic Description
- **The skin around the commissure of the beak and medial canthus of the eye is covered by poorly demarcated, coalescing, raised tan-yellow plaques of dry, crusty tissue.**



Avian pox

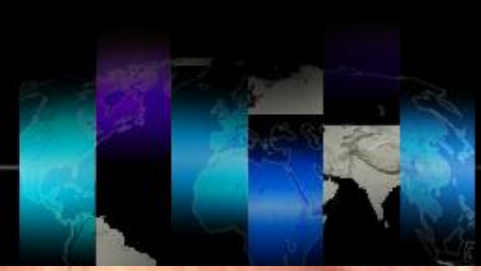

- Morphologic Diagnosis
- **Oral cavity: Severe multifocal to coalescing mucosal hyperplasia. Eye (lid): Focal proliferative blepharitis.**
- Clinical Description
- **This chicken is infected with the wet, or diphtheritic, form of avian pox. There are many yellowish patches on the mucous membranes of the oral cavity and on the tongue. The eyelid is also affected with the dry form of pox. In clinical cases, both wet and dry forms of the disease can be present at the same time.**
- Pathologic Description
- **The oral cavity of the bird is covered by multiple, well-demarcated, raised, slightly granular yellow plaques. These plaques are particularly dense in the tissue surrounding the choanal slit. In this area, they coalesce to form a more extensive lesion. The skin around the eye is swollen and contains a large, well-demarcated, dry, raised mass with a fissured, brown-red surface.**

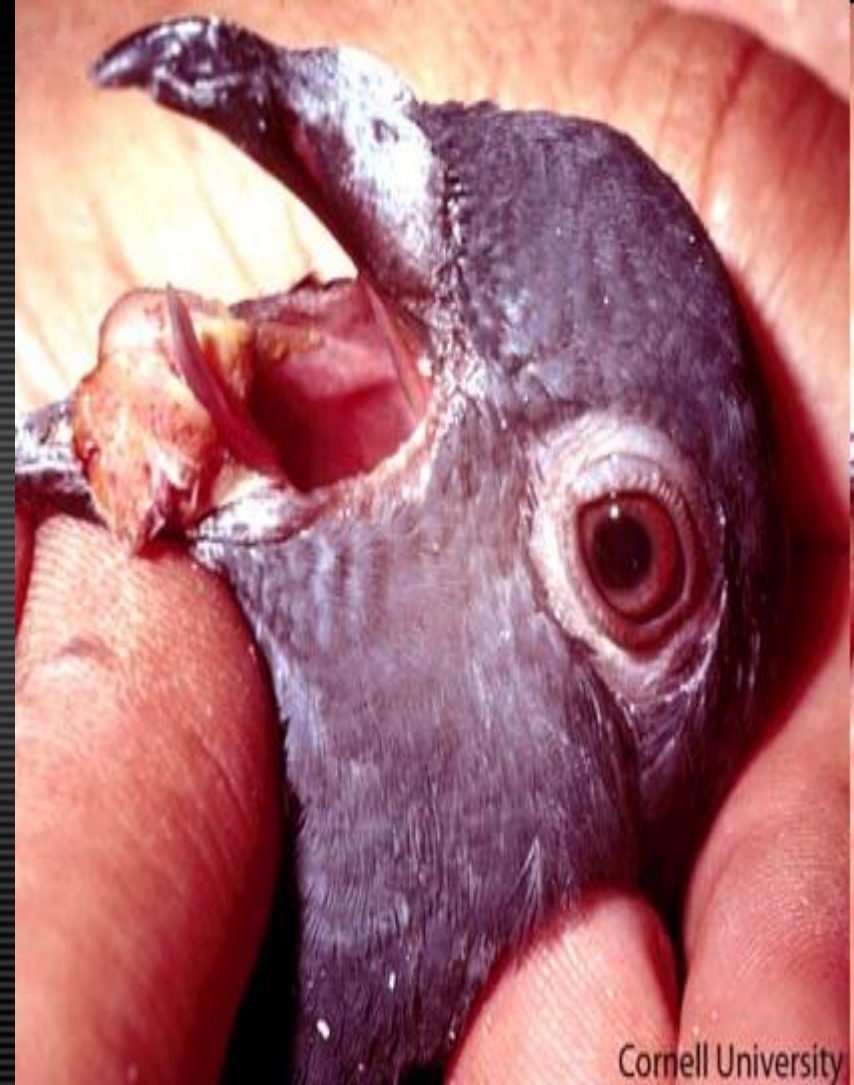

Dr. Jaime Ruiz

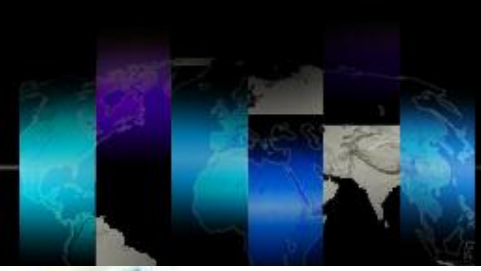Avian pox



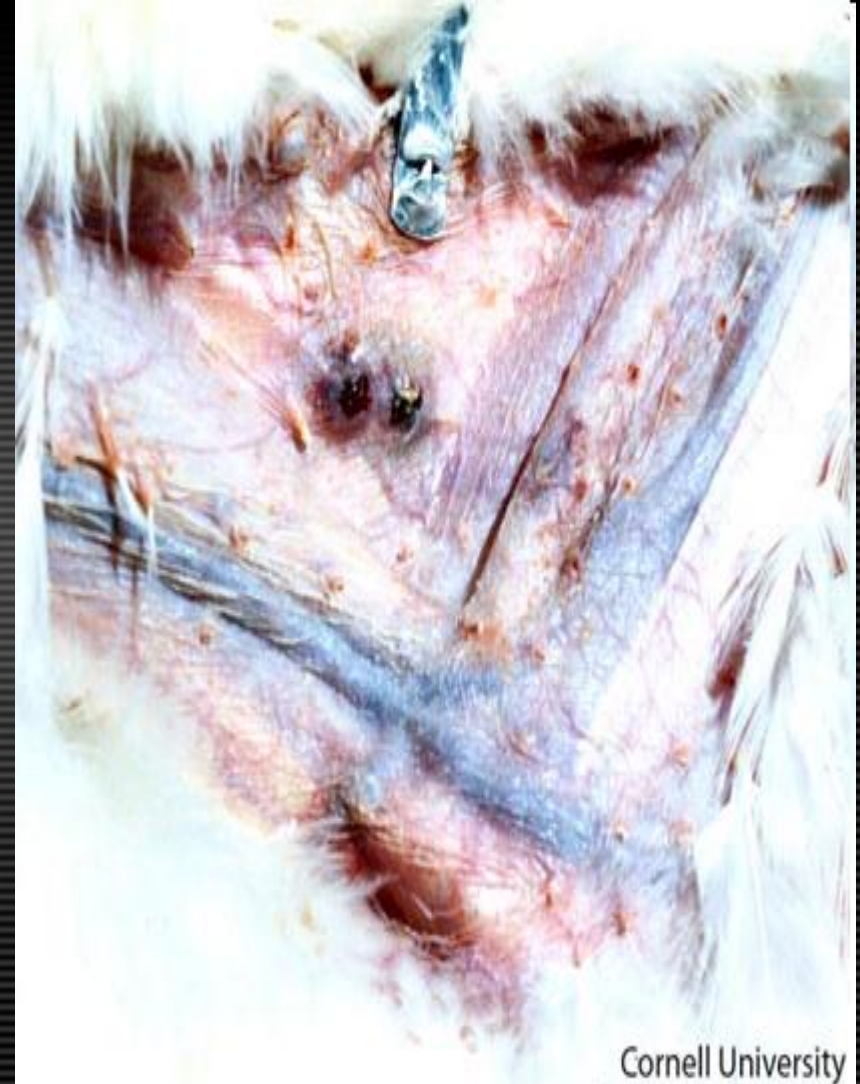- Morphologic Diagnosis
- **Oral cavity: Severe regionally extensive proliferative stomatitis.**
- Clinical Description
- **Large diphtheritic nodules may also be present in the oral cavity.**
- Pathologic Description
- **The cranial portion of the oral cavity is filled by a large, raised pale tan mass that distorts the lower portion of the beak and displaces the tongue. Similar pinpoint tissue proliferations are present along the buccal surface of the mouth. The tissue has a slightly granular surface and is covered by numerous pinpoint red foci.**



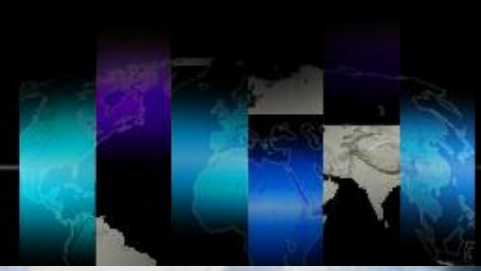Avian pox



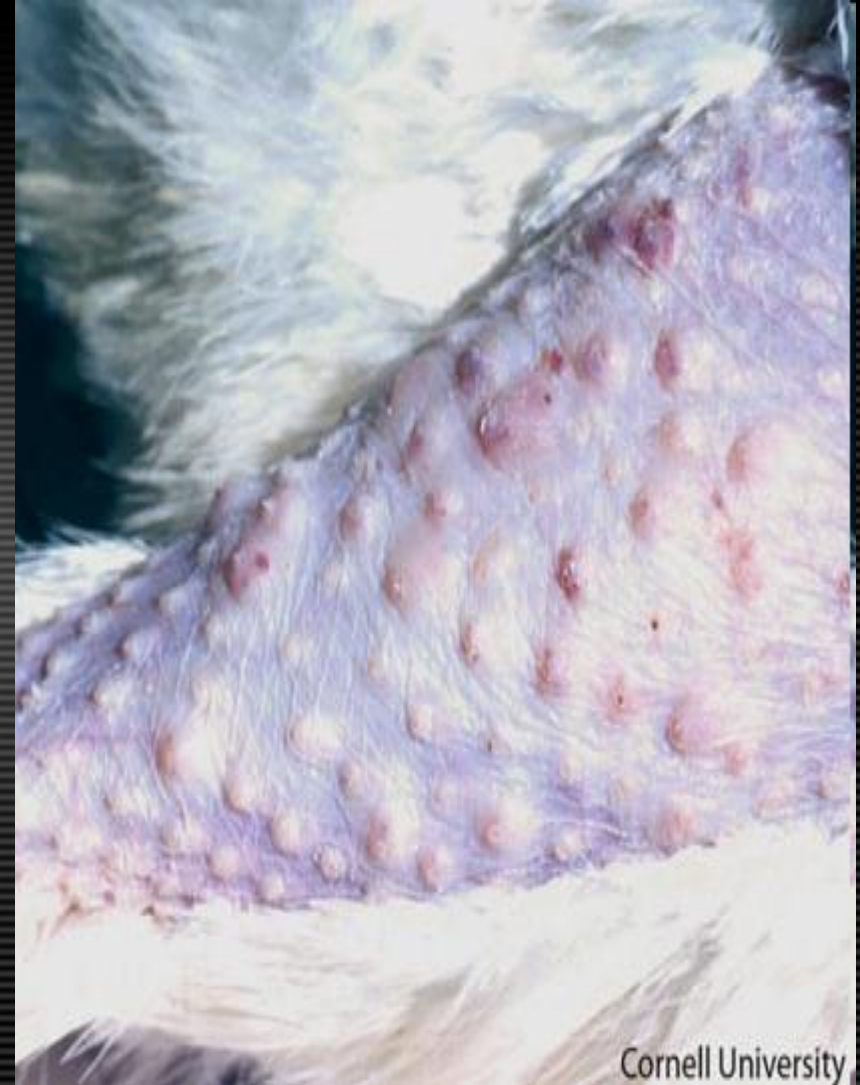- Clinical Description
- **This image shows a vaccine “take” on the chicken’s wing web. A “take” is a swelling of the skin or scab in the site where the vaccine was applied and is evidence of a successful vaccination. When administering the avian pox vaccine in the wing web, special care should be taken to avoid injection in the adjacent veins as this will cause a severe inflammatory response and hemorrhage. If the vaccine is properly administered the majority of the vaccinated birds should develop “takes” 7-10 days post-vaccination.**



Avian pox



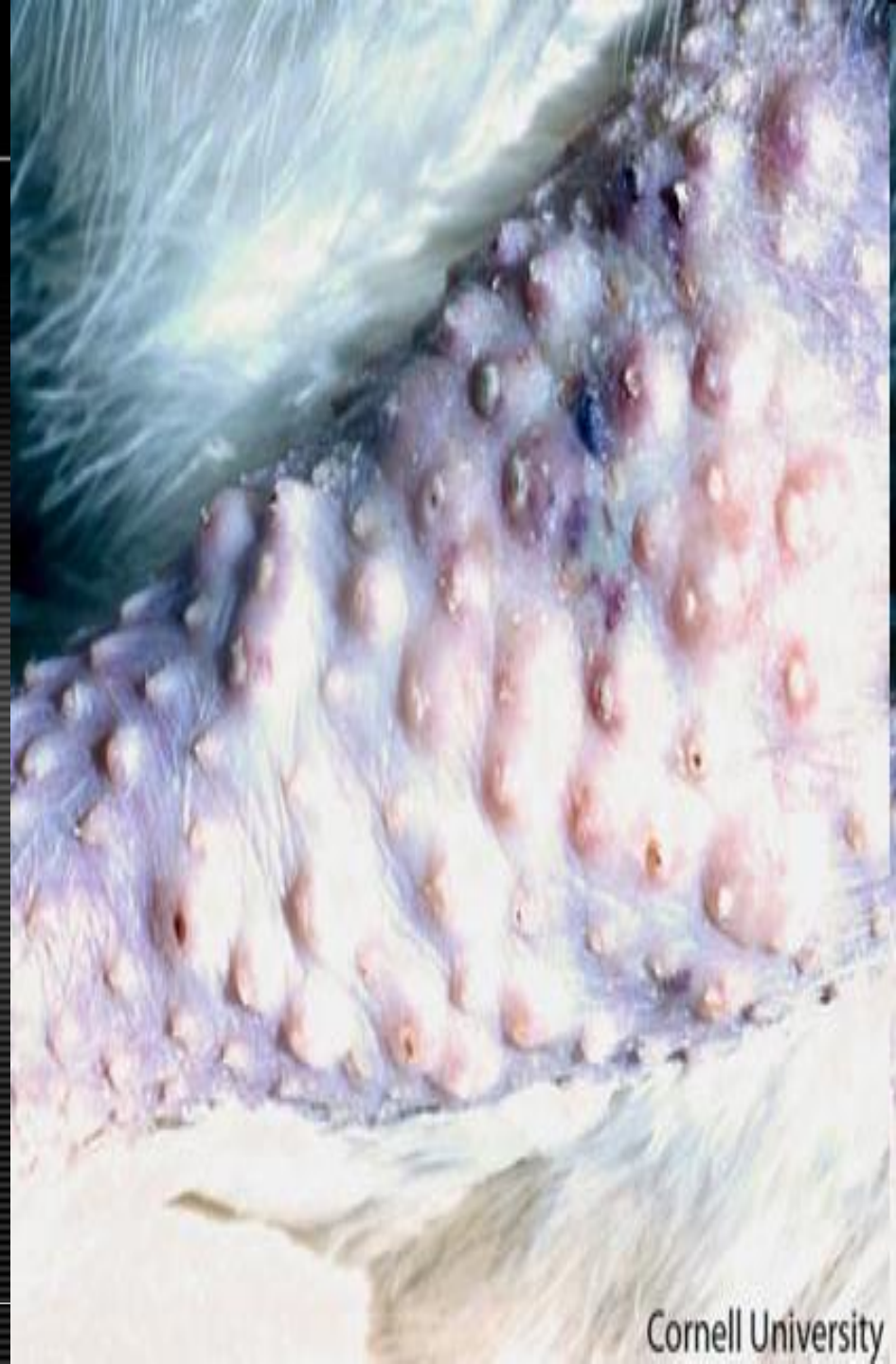
- Morphologic Diagnosis
- **Skin, leg: Severe multifocal follicular epithelial hyperplasia and folliculitis**
- Clinical Description
- **In this photograph, an early stage of the cutaneous (dry) form of avian pox is illustrated. Pox virus is slow-spreading and skin lesions change over a period of approximately 2-8 weeks. Lesions progress from nodules, to small white foci, papules, vesicles, scabs, and eventually scars. In this photo, local epithelial hyperplasia of the follicles has produced numerous raised nodules.**
- Pathologic Description
- **The feather follicles on the leg of this chicken are distended, nodular, and swollen. Many of the follicles are slightly red and some of them have a small crusts on their surface.**



Cornell University

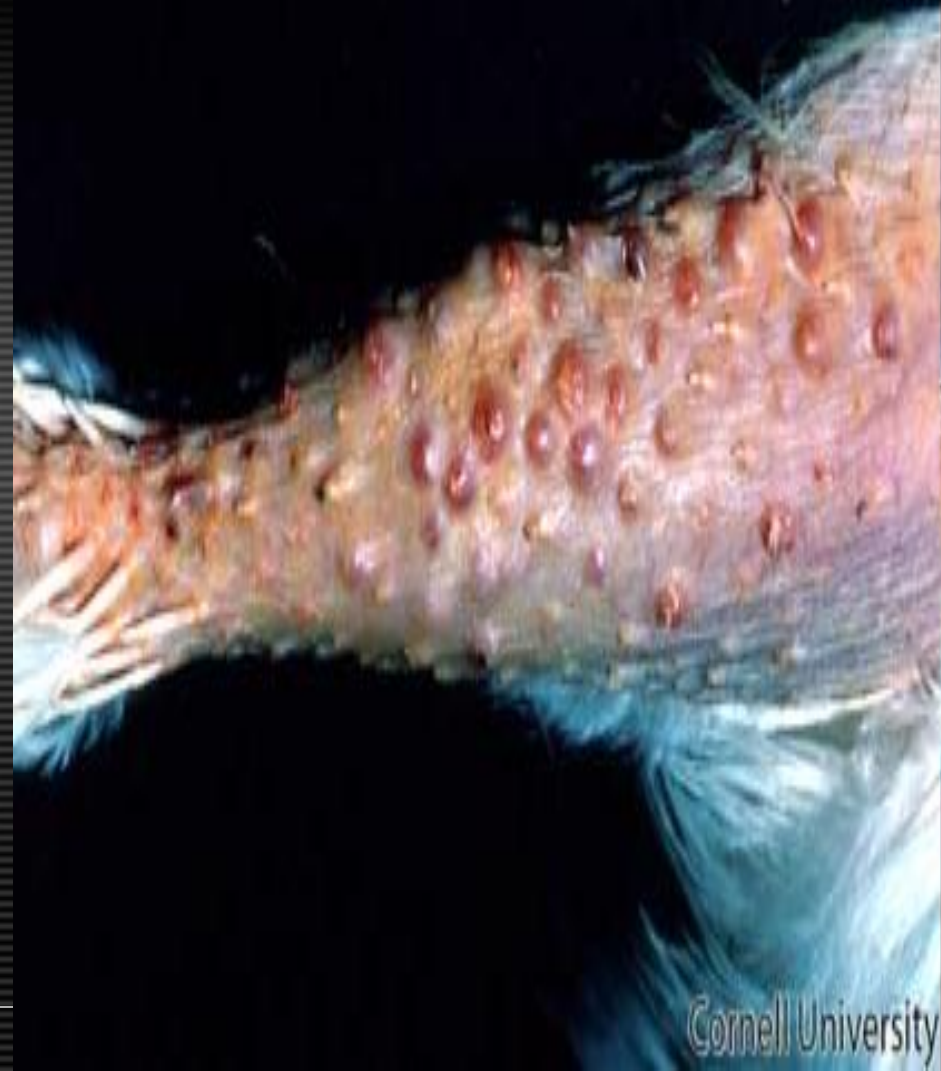Avian pox

- Morphologic Diagnosis
- **Skin, leg: Multifocal follicular epithelial hyperplasia with folliculitis and hemorrhage**
- Clinical Description
- **In this photograph of a chicken infected with pox virus, the skin nodules caused by epithelial hyperplasia have reached a more advanced stage. Lesions will progress from nodules, to small white foci, papules, vesicles, scabs, and eventually scars.**
- Pathologic Description
- **The skin of this leg is covered by multiple distended follicles. Some of these follicles are red and some of the intra-follicular skin contains small hemorrhages. Many of the follicles are covered by a small brown crusts.**



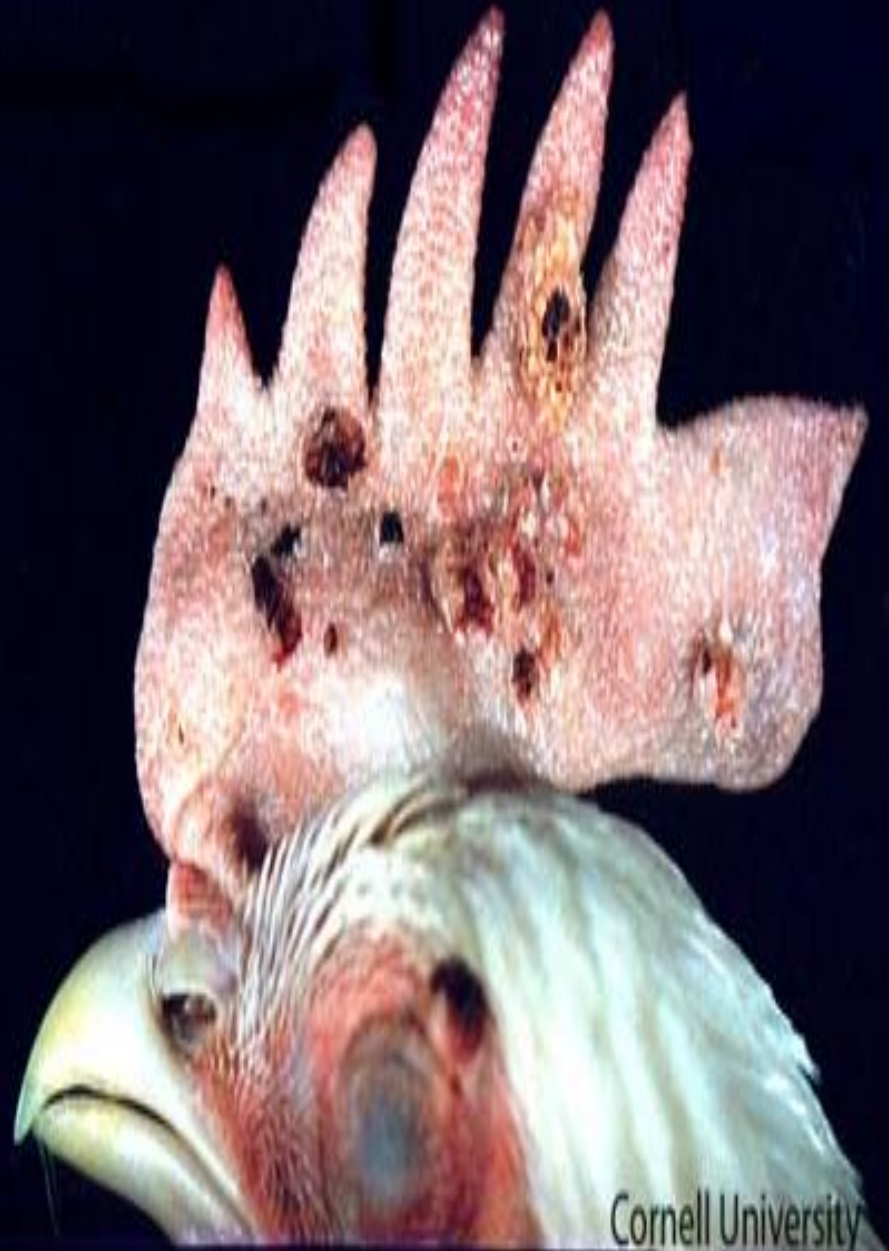Avian pox

- Morphologic Diagnosis
- **Skin: Multifocal proliferative folliculitis.**
- Clinical Description
- **Cutaneous (dry) form of avian pox with proliferative lesions in the papular and vesicular stages.**
- Pathologic Description
- **The feather follicles along the leg of this chicken are swollen and some are slightly reddened.**



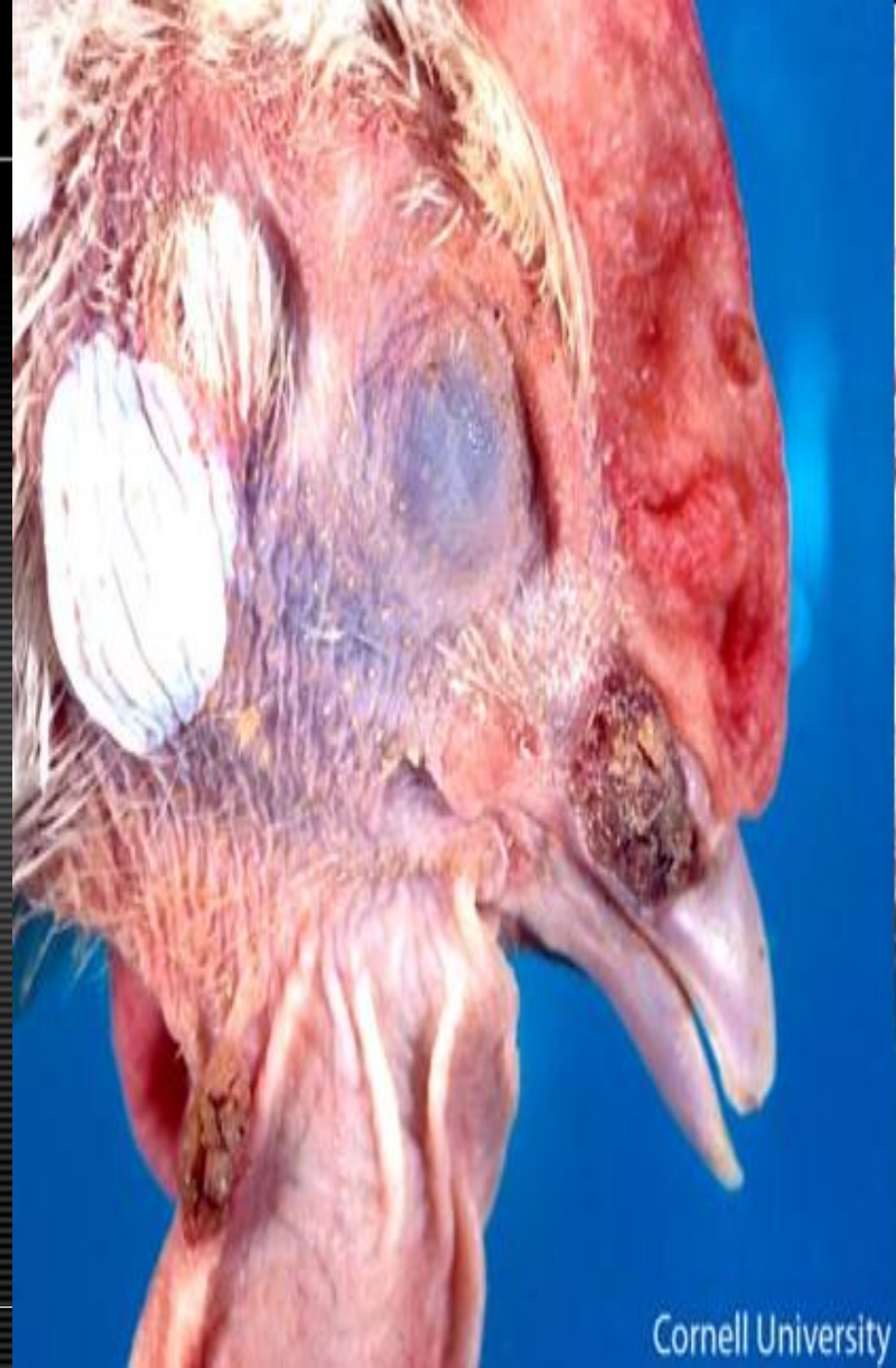Avian pox

- Morphologic Diagnosis
- **Skin (comb): Multifocal hyperplasia with ulceration.**
- Clinical Description
- **In this photograph, a late stage of the cutaneous (dry) form of avian pox is illustrated in the comb. Pox virus is slow-spreading and skin lesions change over a period of approximately 2-8 weeks. Lesions progress from nodules, to small white foci, papules, vesicles, scabs (seen here), and eventually scars.**
- Pathologic Description
- **The comb of this chicken is covered by multiple, well-demarcated raised nodules. The nodules are pale tan, to slightly yellow and the majority of them are centrally ulcerated and covered by dark scabs.**



Avian pox

- Morphologic Diagnosis
- **Skin (cere and wattle): Multifocal hyperplasia with hyperkeratosis and ulceration.**
- Clinical Description
- **Cutaneous (dry) form of avian pox with proliferative lesions and scab formation on the nare and wattle.**
- Pathologic Description
- **The skin of the cere and caudal edge of the wattle is extensively expanded by raised, well-demarcated, irregular masses covered by flaky brown material. The mass on the beak partially occludes the nare and is partially covered by layers of red, dry material (scab.)**



Avian pox

- Morphologic Diagnosis
- **Skin (body): Multifocal proliferative and ulcerative nodular dermatitis.**
- Clinical Description
- **Cutaneous (dry) form of avian pox with numerous proliferative lesions on the skin (de-feathered for this photo) of the entire body. Typical pox lesions are often found on the head and other nonfeathered areas however, it is possible for lesions to form on other regions of the body.**
- Pathologic Description
- **The carcass of this bird has been defeathered to reveal numerous, variably-sized, cutaneous masses over the body. The masses are well-demarcated, raised, roughly spherical and range from being broad-based to pedunculated. The body of the masses are pale tan and many of the masses are covered by variably thick crusts of dried blood and serum.**



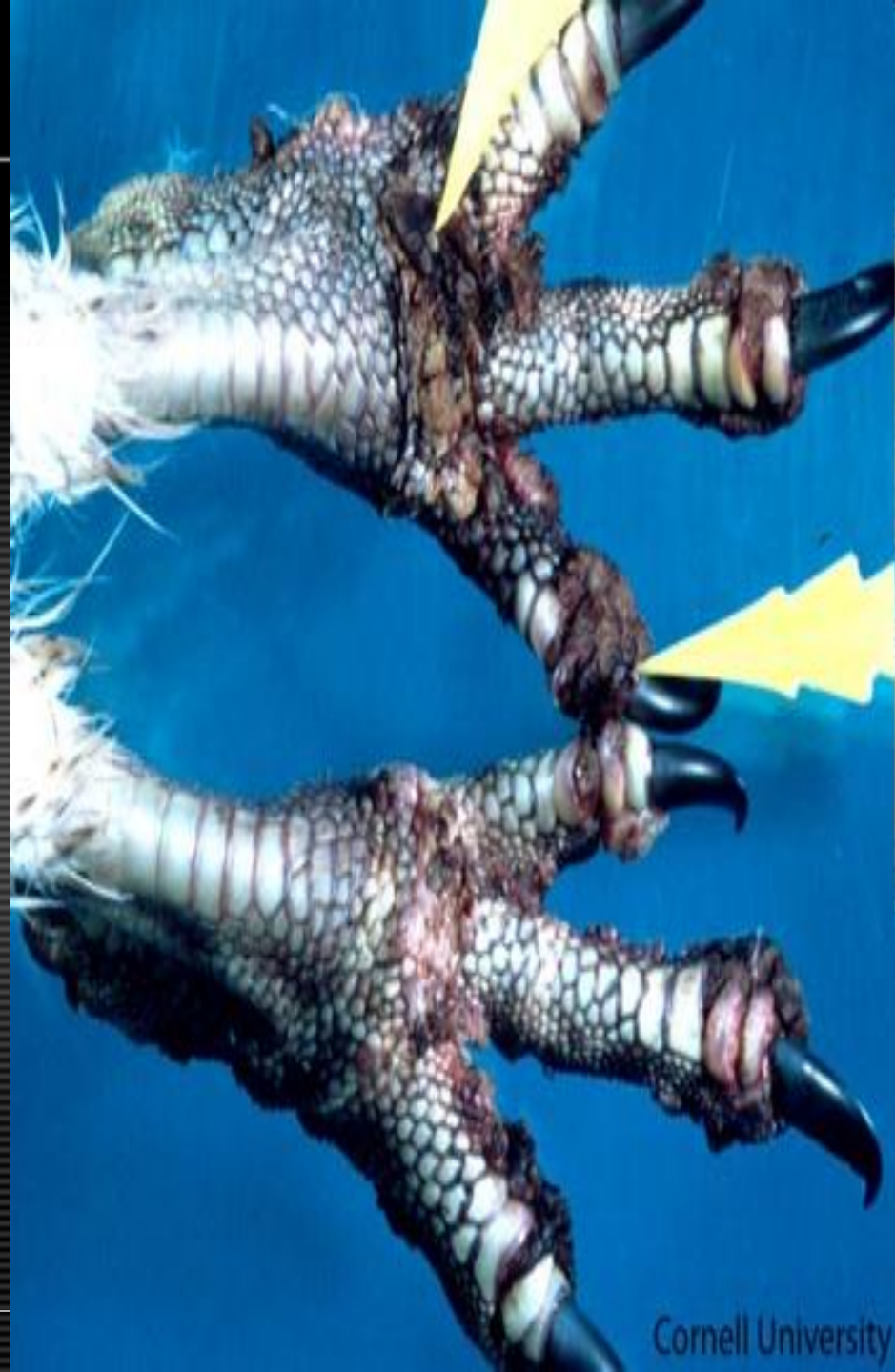
Avian pox

- Morphologic Diagnosis
- **Skin (body): Multifocal to coalescing proliferative and hyperkeratotic dermatitis.**
- Clinical Description
- **This image shows the dry, or cutaneous, form of avian pox. There are many pox lesions along the dorsum of this table-egg layer. Pox lesions typically develop on the head and legs however, in rare cases, they may extend into other regions of the body. The lesions are cutaneous nodules of epithelial hyperplasia arising from of the epidermis and feather follicles.**
- Pathologic Description
- **The skin of the body, face, wattles and comb of these chickens is covered by multiple, well-demarcated, regionally coalescing, raised, dry brown masses. The majority of the masses are brown-grey, covered in flaky material and have a crateriform surface. Some of the masses on the unfeathered skin consist of superficial regions composed of brown flaky material, surrounded by smoother, paler raised tissue and a few of the masses are delineated by a thin rim of red tissue. The lesions on the face impinge on the eye and nare.**



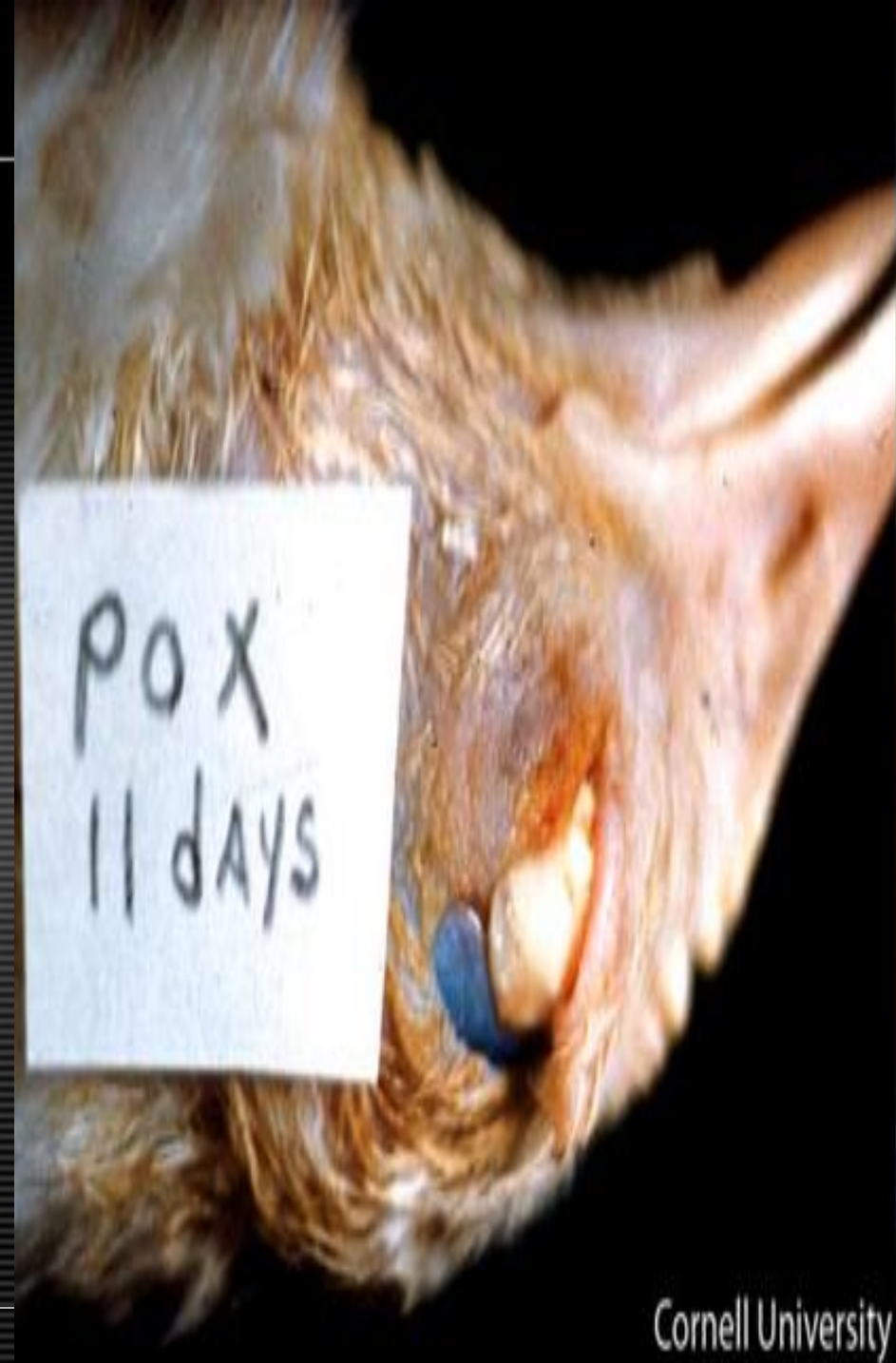Avian pox

- Morphologic Diagnosis
- **Skin (feet): Multifocal proliferative and ulcerative dermatitis.**
- Clinical Description
- **As seen here, in the cutaneous form of pox, proliferative lesions may develop on the feet and digits.**
- Pathologic Description
- **The skin of the feet and digits is distorted by multiple, poorly-demarcated, slightly raised, encrusted lesions that are particularly prominent on the dorsum of the foot at the top of the picture. The majority of the lesions are brown, replace the normal scales of the foot and extend into the interdigital spaces. Many of the lesions, especially those between the toes, are red and wet.**



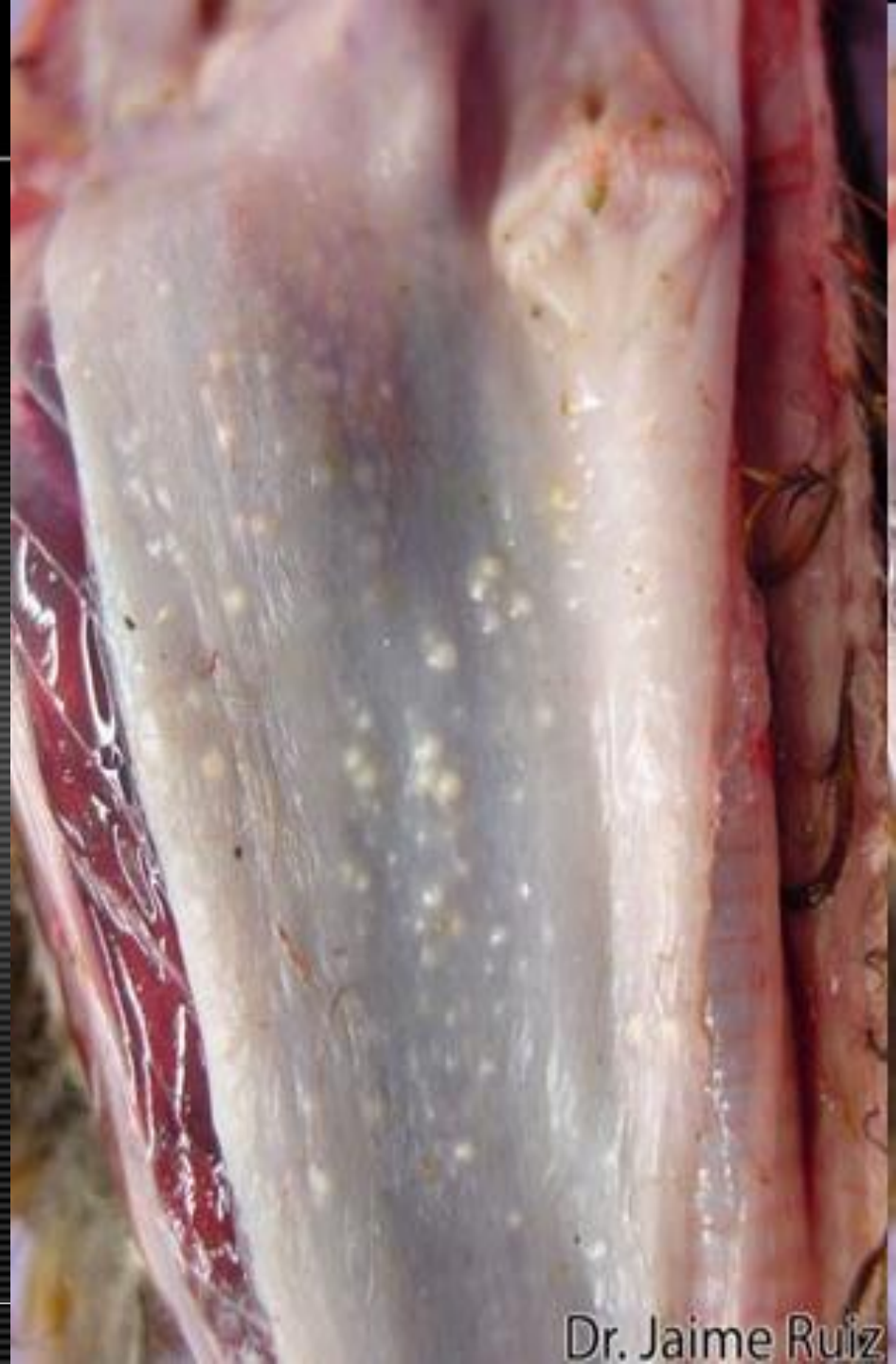Avian pox

- Morphologic Diagnosis
- **Conjunctiva: Diffuse hyperplasia with fibrinonecrotic conjunctivitis.**
- Clinical Description
- **Diphtheritic (wet) form of avian pox with fibrino-necrotic proliferative lesions on the conjunctiva.**
- Pathologic Description
- **The conjunctiva of this bird is largely replaced by a large, raised, well-demarcated, pale tan mass partially covered along the medial aspect by a layer of light, slightly wet, friable material**



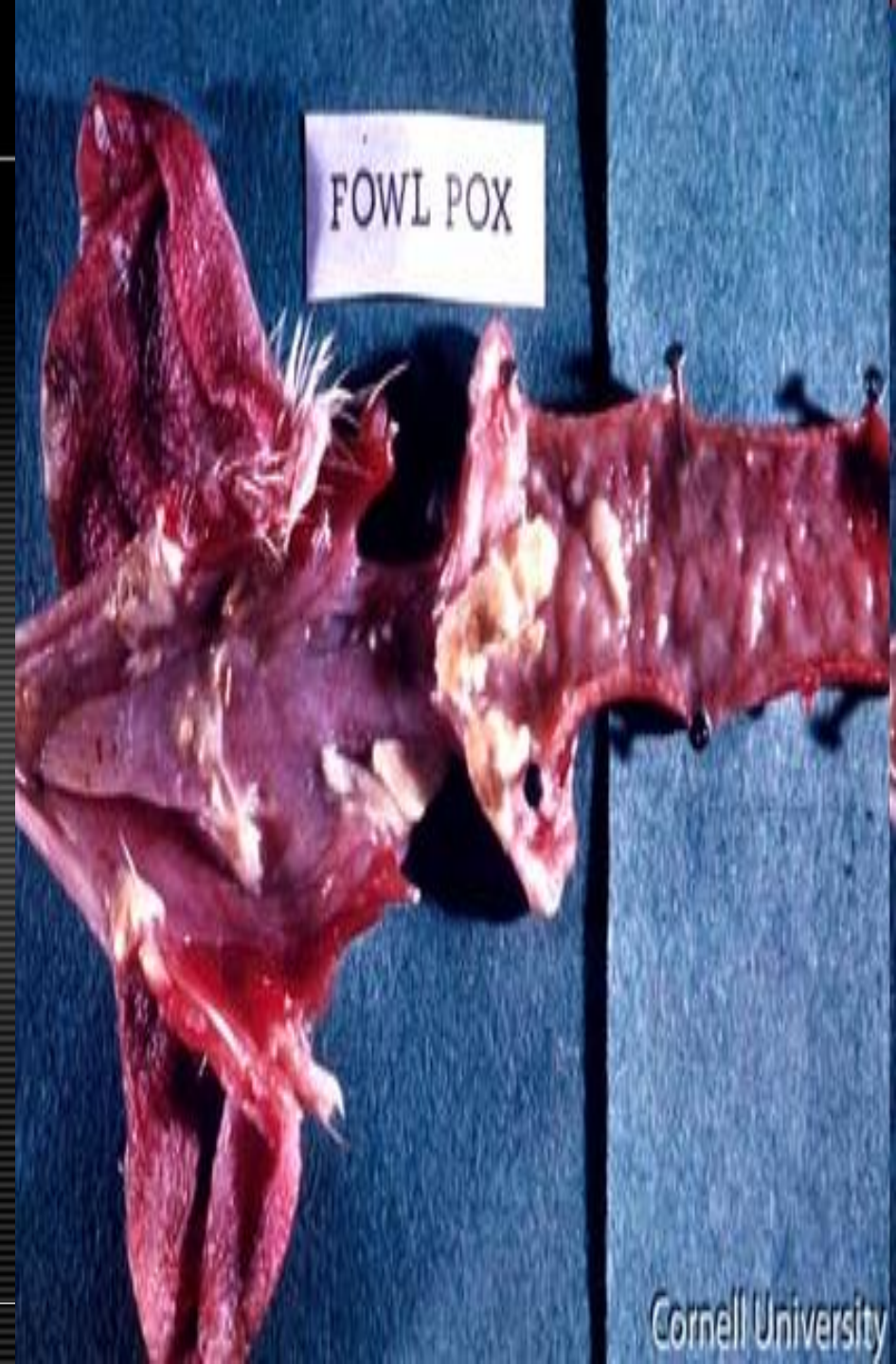Avian pox

- Morphologic Diagnosis
- **Esophagus (mucosa): Multifocal hyperplasia.**
- Clinical Description
- **In the wet, or diphtheritic form of Avian Pox, mucous membranes may become affected. This image of the esophagus shows many white pinpoint nodules on the mucosa.**
- Pathologic Description
- **The proximal esophagus has been opened to reveal the mucosal surface. The mucosa is covered by numerous, small, raised, well-demarcated pale tan masses. These masses are scattered randomly along the mucosal surface.**



Avian pox

- Morphologic Diagnosis
- **Trachea: Diffuse tracheitis with locally extensive diphtheritic membrane.**
- Clinical Description
- **This image shows typical diphtheritic lesions on the trachea, caused by avian pox. The fibrino-necrotic proliferative lesions form on mucous membranes. In the early stages, these plaques begin as as small white opaque nodules that frequently enlarge into larger yellow diphtheritic membranes. These lesions may develop in the oral cavity, tongue, esophagus, or upper trachea. If the lesions are located in the lower respiratory tract (e.g. the syrinx), they can compromise breathing, resulting in dyspnea.**
- Pathologic Description
- **The trachea has been opened to reveal the mucosal surface. The proximal trachea is covered by a large coagulum of pale yellow, friable material that is adherent to the underlying mucosa. The remaining tracheal mucosa is red, glistening and undulating.**



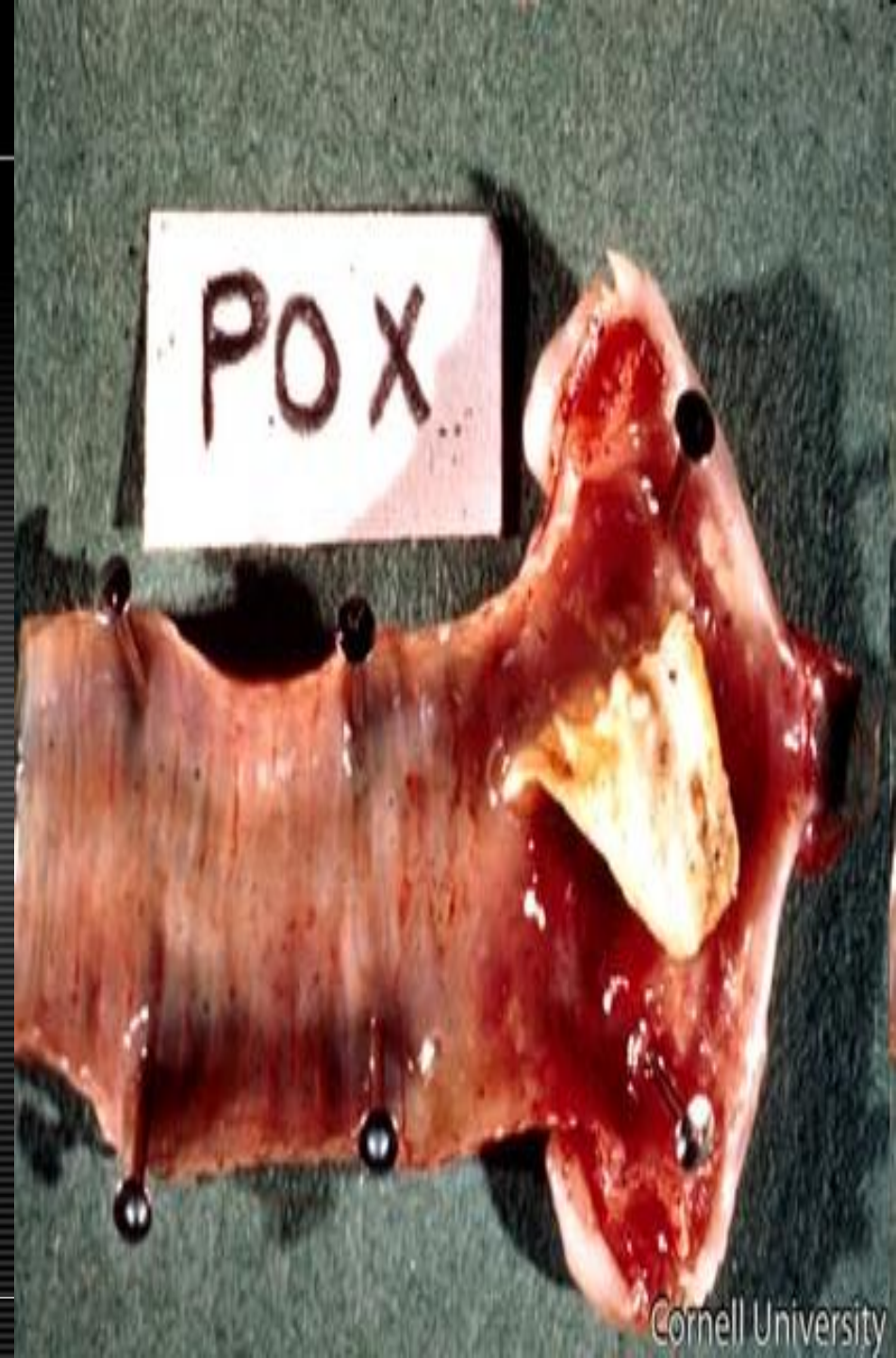Avian pox

- Morphologic Diagnosis
- **Trachea: Diffuse necrosuppurative tracheitis with locally extensive diphtheritic membrane.**
- Clinical Description
- **This image shows a typical diphtheritic lesion caused by avian pox. The fibrino-necrotic proliferative lesions form on mucous membranes. These lesions may develop in the oral cavity, tongue, esophagus, or upper trachea. If the lesions are located in the lower respiratory tract (e.g. the syrinx), they can compromise breathing, resulting in dyspnea.**
- Pathologic Description
- **The trachea has been partially opened to reveal the mucosal surface which is diffusely red. Within the lumen there is a focal accumulation of wet, pale tan, mucoid material along with a partially occlusive plug composed of dry, friable, yellow tan material.**



Avian pox

- Morphologic Diagnosis
- **Trachea: Locally extensive fibrinonecrotic tracheitis with multifocal petechia.**
- Clinical Description
- **Diphtheritic (wet) form of avian pox. On post-mortem examination, if these diphtheritic membranes are removed, bleeding erosions are sometimes found beneath these membranes.**
- Pathologic Description
- **The trachea has been opened to reveal the mucosal surface. Within the cranial portion of the esophagus (right side of picture) there is a large aggregate of dry, pale tan, friable material. The material overlies a bright red and wet section of mucosa. Small pinpoint red foci are scattered along more distal portions of the tracheal mucosa.**

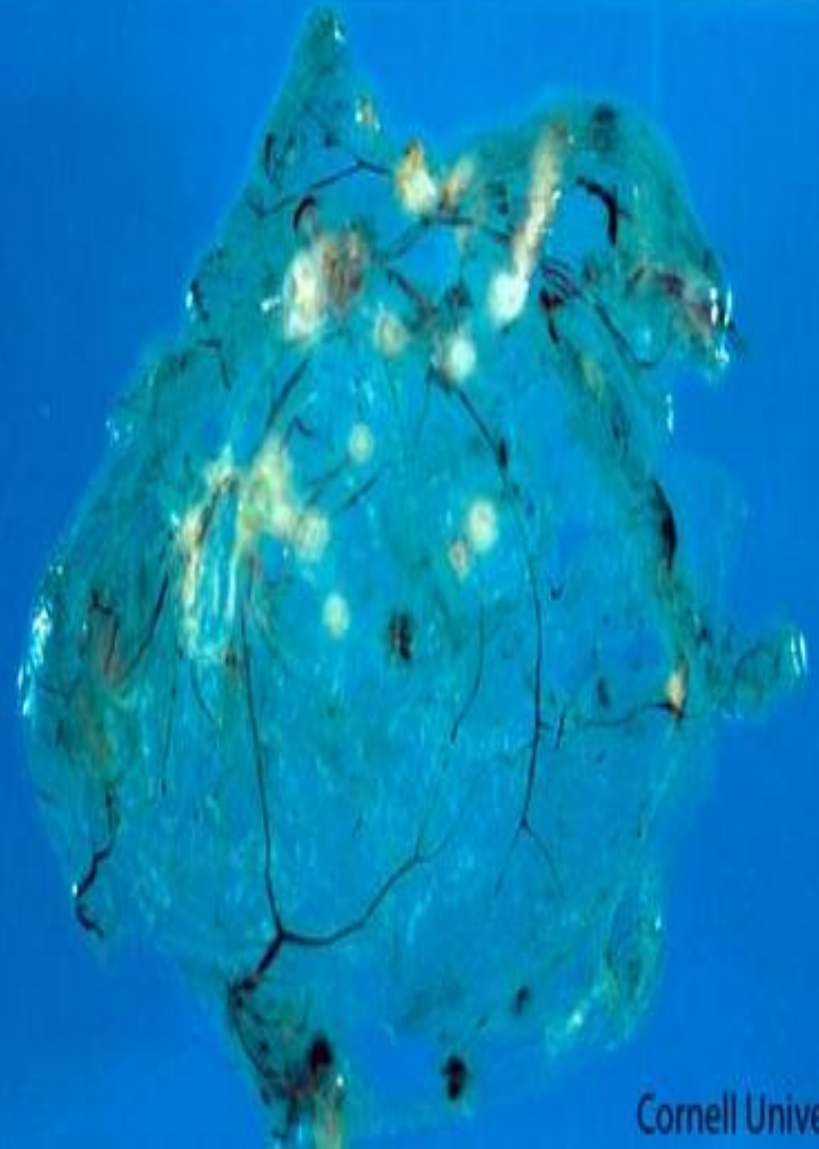

Avian pox

- Morphologic Diagnosis
- **Chorioallantoic membrane: Multifocal hyperplasia.**
- Clinical Description
- **In laboratory diagnosis of avian pox, chicken embryo inoculation is one of the best methods to identify typical lesions induced by this virus. Here, white opaque pock lesions have developed 6 days post-inoculation on the chorioallantoic membrane (CAM) of a chicken embryo inoculated with poxvirus.**
- Pathologic Description
- **The normally transparent tissues of the chorioallantoic membrane are disrupted by multiple, well-demarcated, raised, pale yellow plaques.**

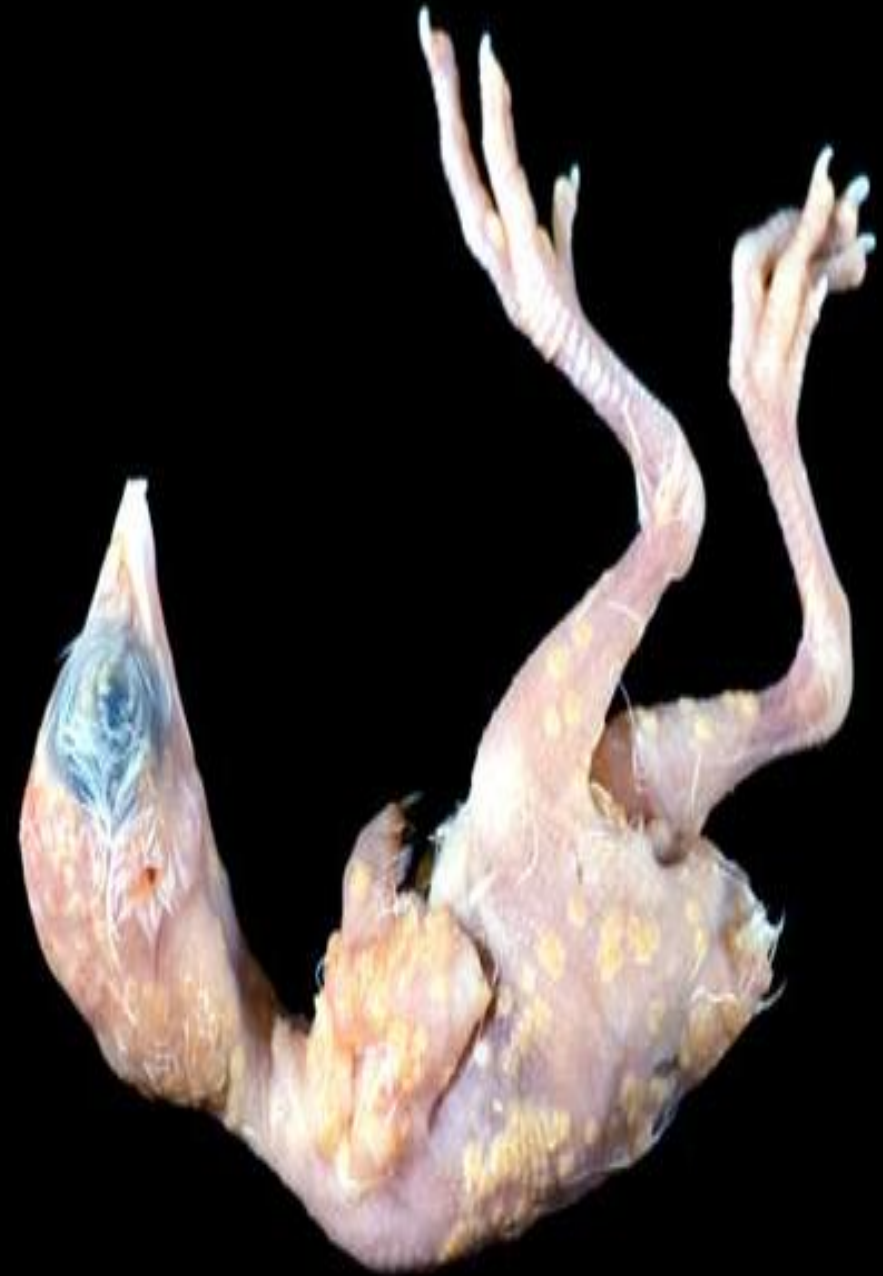FOWL POX VIRUS

Plaques 6 days postinoculation




Avian pox

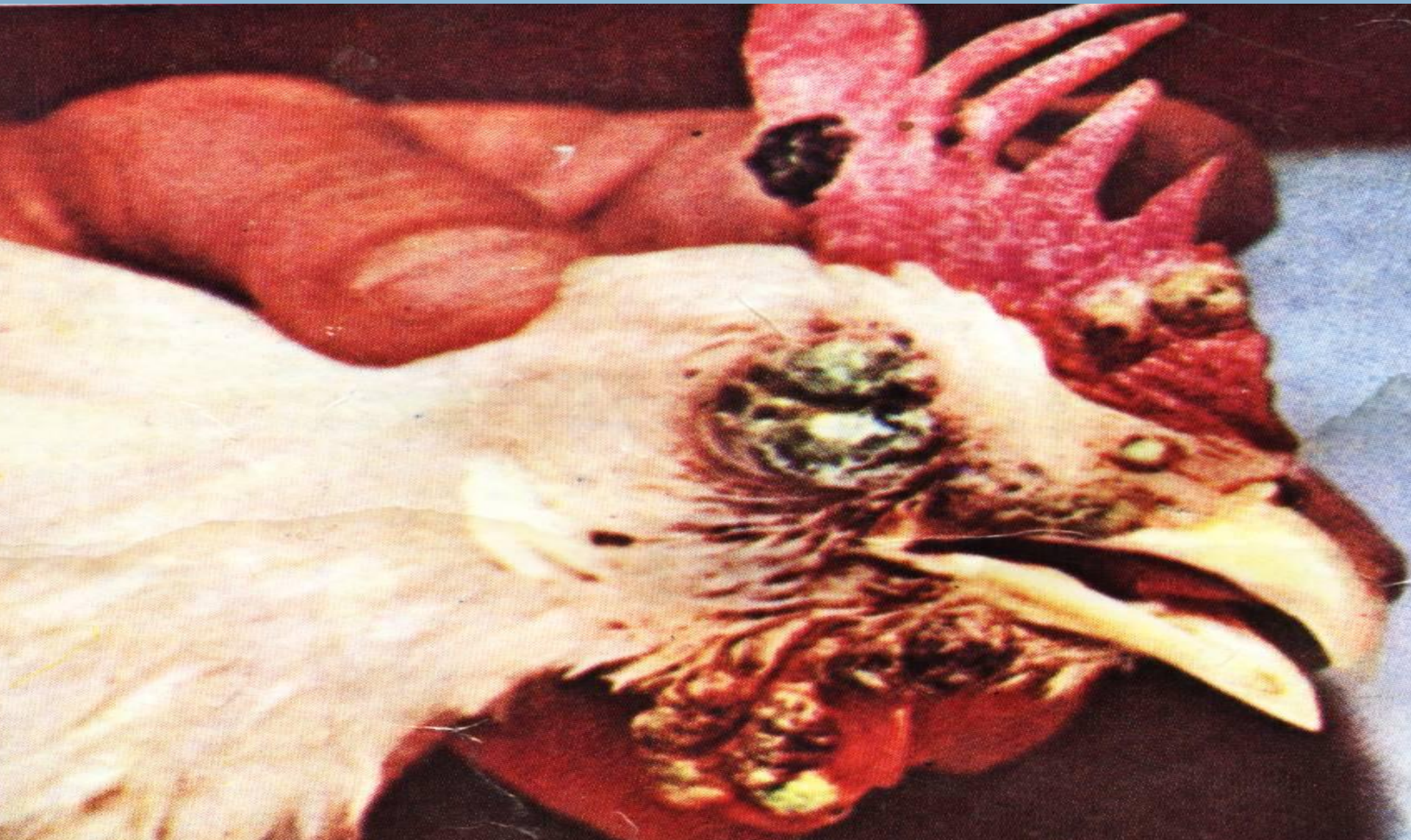- Morphologic Diagnosis
- **Skin: Multifocal to coalescing hyperplasia.**
- Clinical Description
- **This chicken embryo has extensive cutaneous (dry) proliferative lesions across the entire body. This embryo was experimentally inoculated with avian pox virus. In natural infections, pox virus is transmitted through direct contact or mechanical vectors, such as mosquitoes and mites.**
- Pathologic Description
- **The skin of the embryo is covered by numerous, variably sized, sometimes coalescing pale yellow, raised plaques.**



[Redacted text]



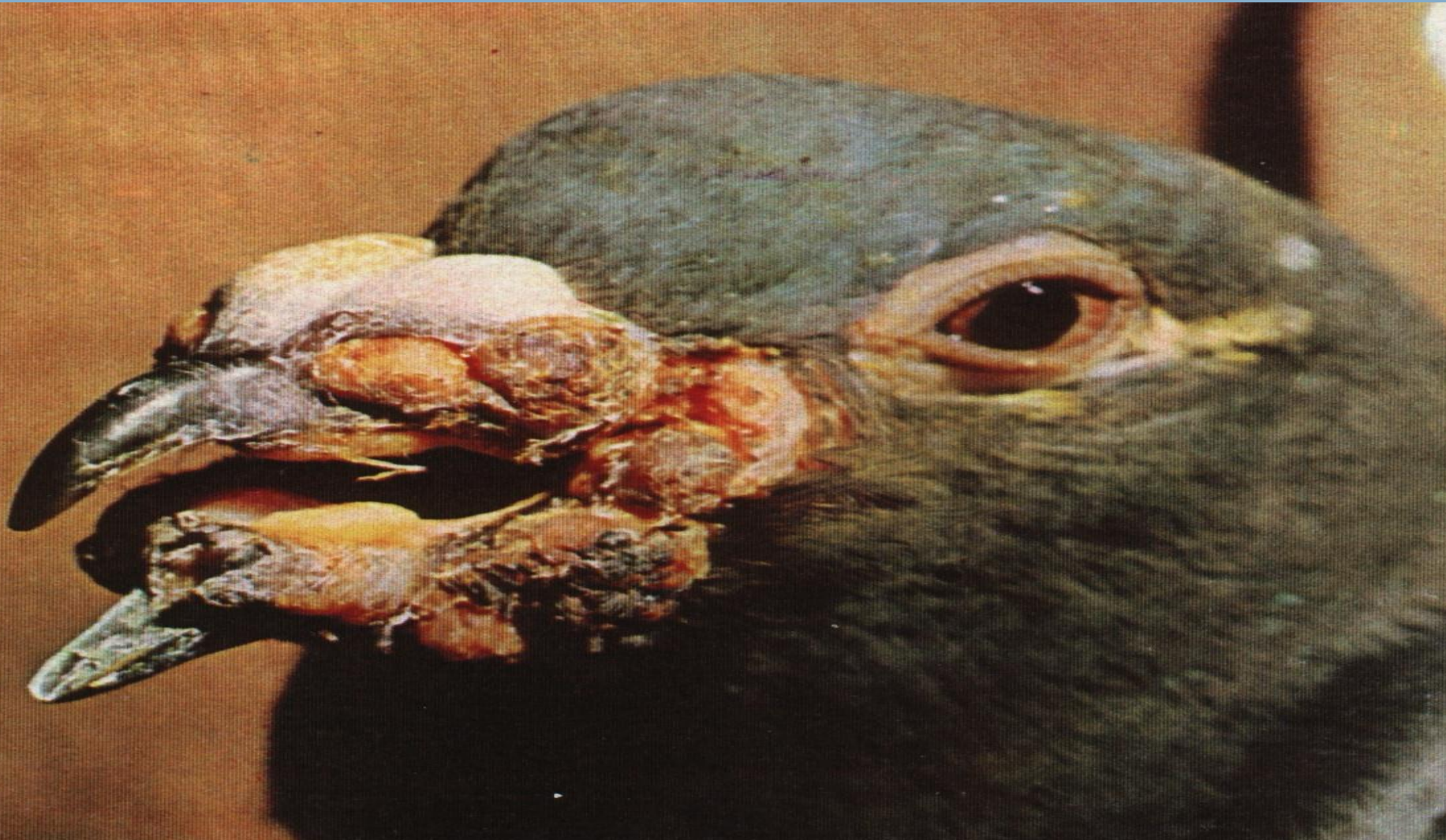ORGAN : Head of chicken
LESIONS : Wart like nodules
SUSP.DIS. : Dry form of fowl pox



ORGAN : Buccal cavity
LESIONS : Diphtheretic lesions
SUSP.DIS. : Wet form of fowl pox



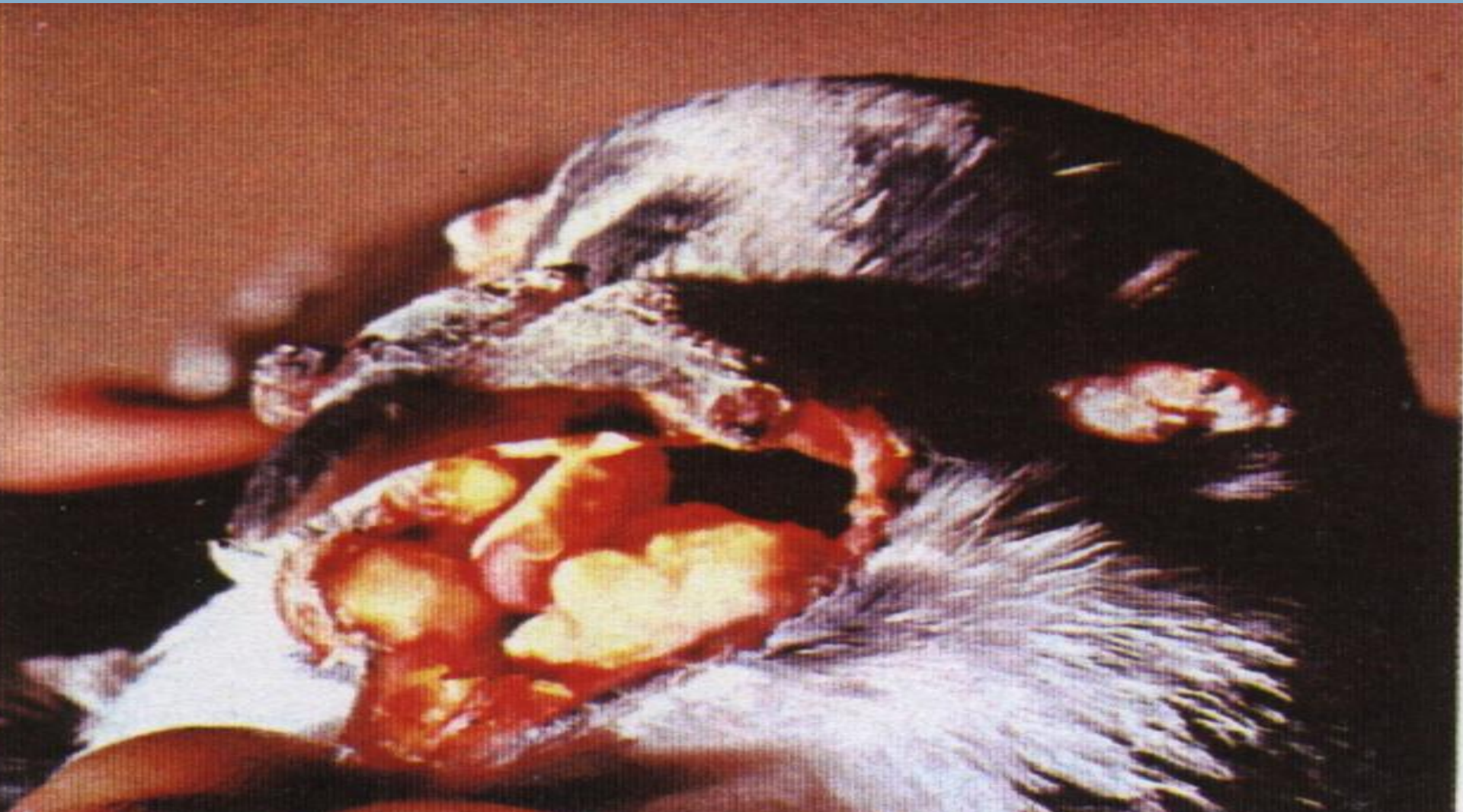ORGAN : Head of pigeon
LESIONS : Wart like nodules and diphtheretic membrane in the buccal cavity
SUSP.DIS. : Mixed form of pigeon pox



ORGAN : Head of pigeon

LESIONS : Diphtheretic lesions and difficult breathing

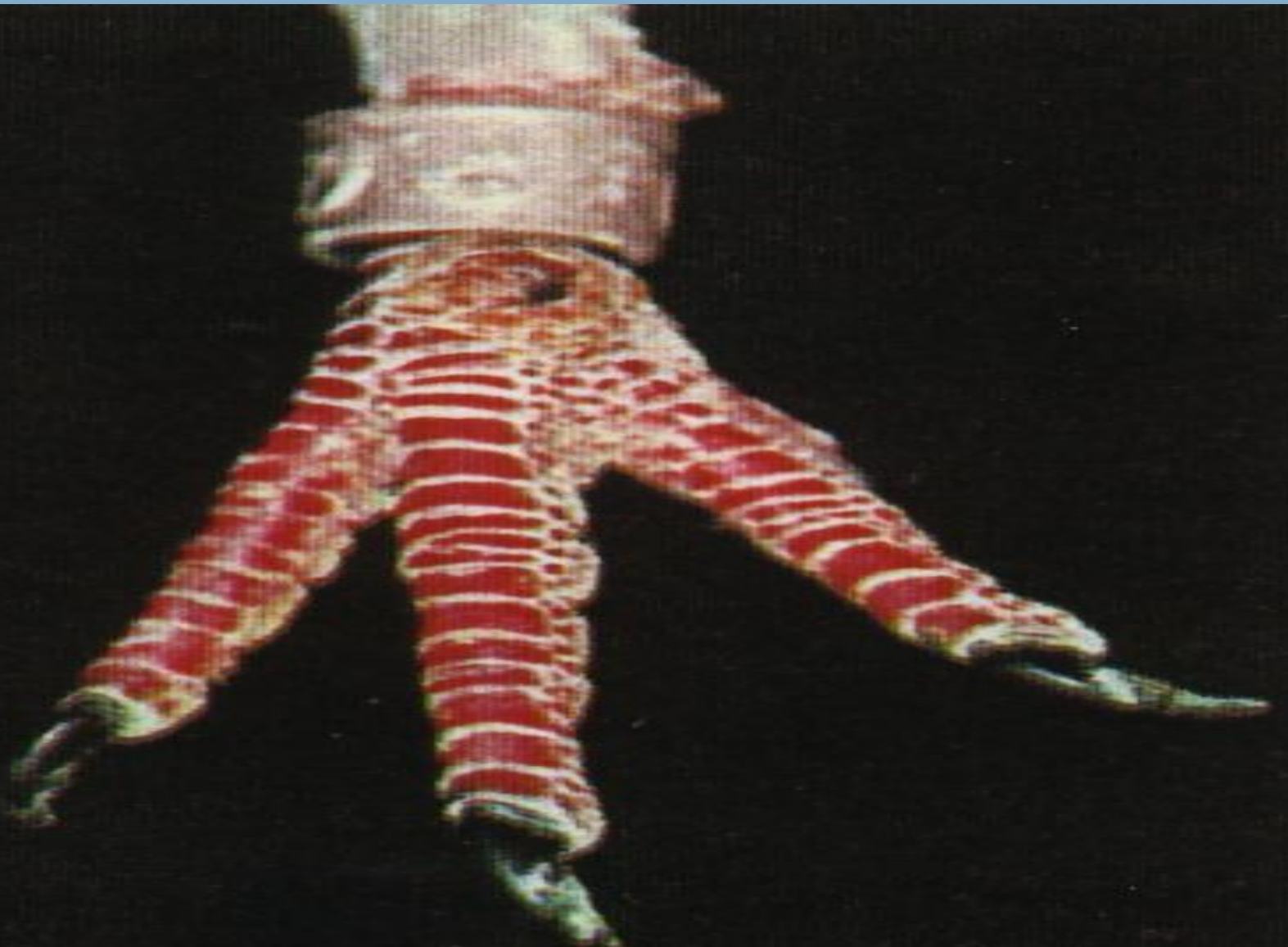
SUSP.DIS. : Wet form of pox



ORGAN : Leg of pigeon

LESIONS : Nodule on ankle Joint

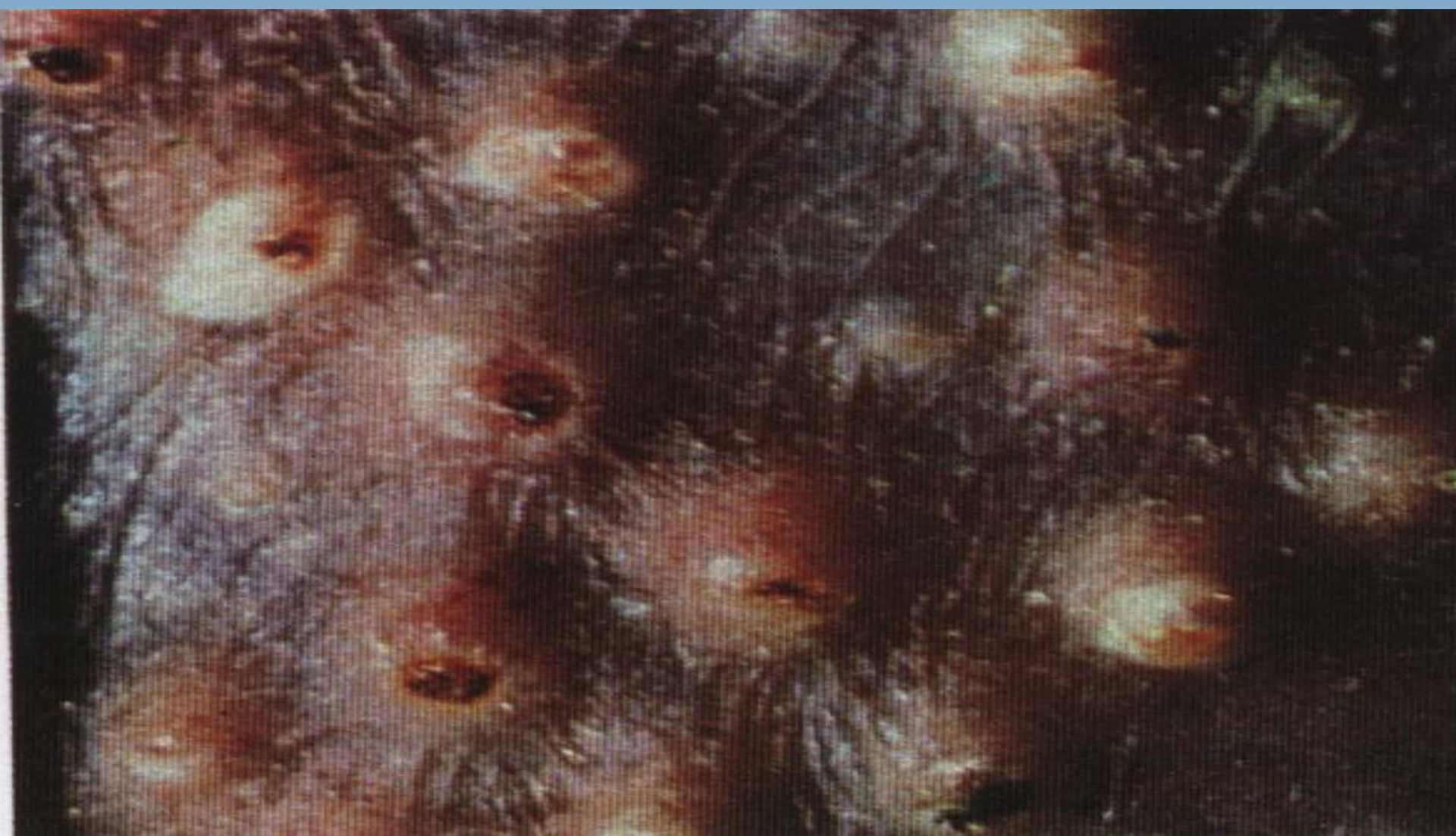SUSP.DIS. : Dry form of pigeon Pox

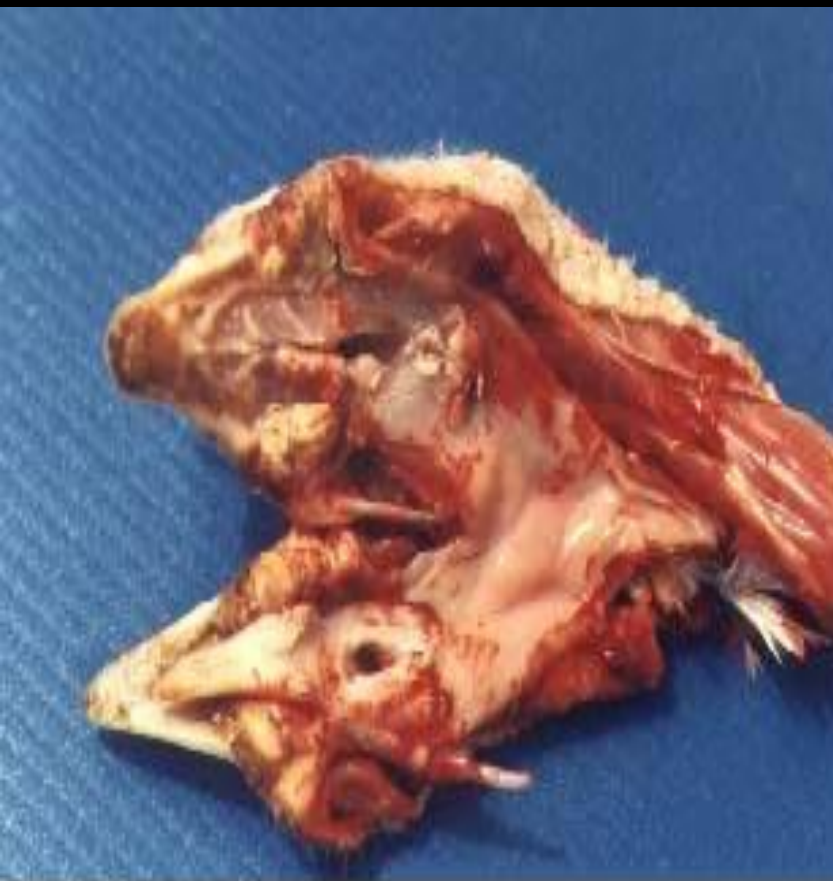

ORGAN : Feather follicle

LESIONS : Small scattered raised spots 5 days after vaccination

SUSP.DIS. : Pox vaccinal takes






Diphtheric form - yellowish, necrotic, cheesy pseudomembranes on the mucous membranes of the mouth.



Focal lesions on the comb.



Coalescence of adjoining foci on the comb and wattle.



Focal lesions - angle of the beak.



Diphtheric form - corner of the mouth.



Focal lesions.

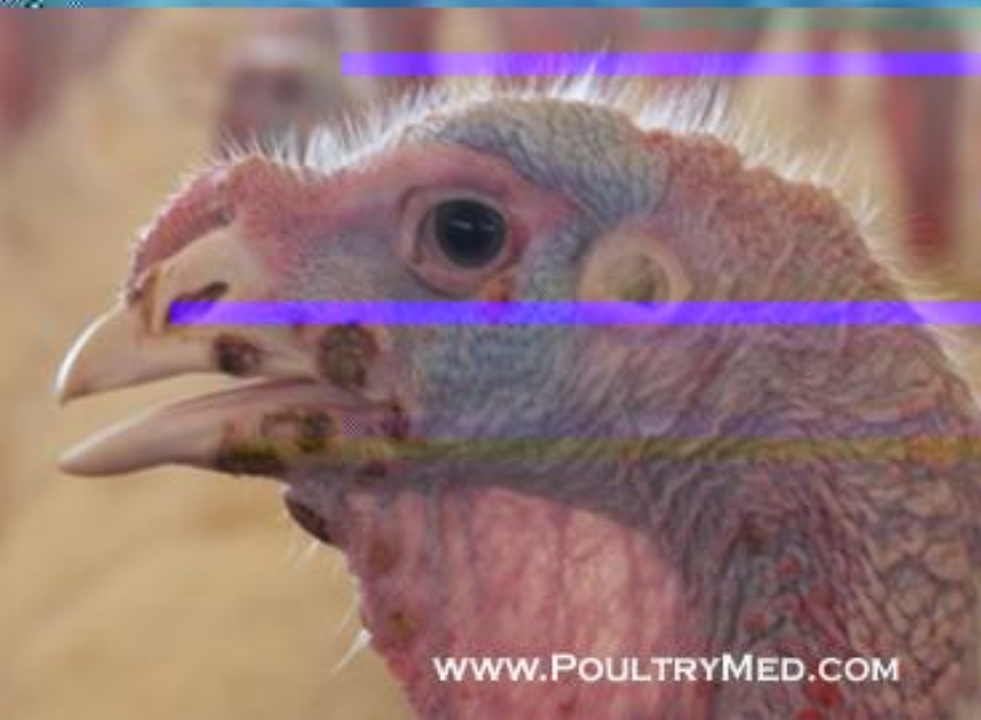

Pigeon - a complete eye closure, due to pox lesions on the eyelid.



Foac1 lesions - angle of the beak.

Pigeon - focal lesions on the beak & eyelid.



Foal lesions in 17 weeks old turkey